

PELVIC CAVITY AND NEUROVASCULAR STRUCTURES

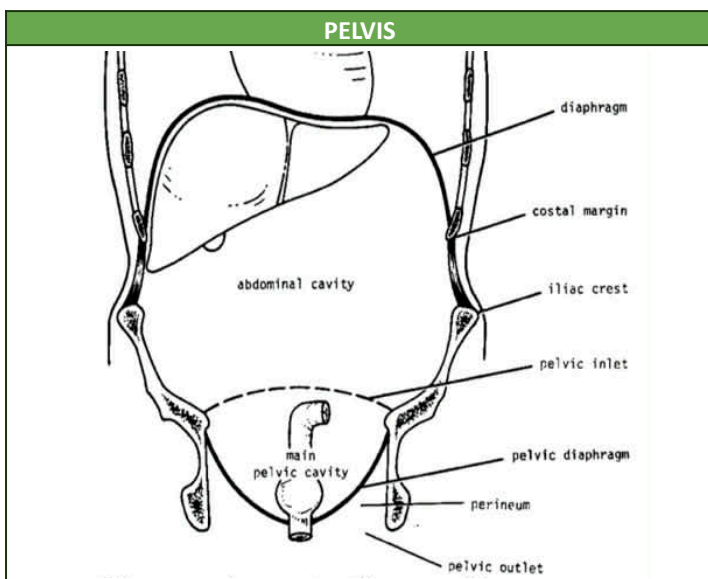
TOPIC OUTLINE:	
1	Pelvic Cavity Definition
2	Differences in Male and Female Pelvic Cavity
3	Muscles of the Pelvic Cavity
4	Neurovascular Structures
5	Clinical Correlations
6	Summary Tables

Legend:

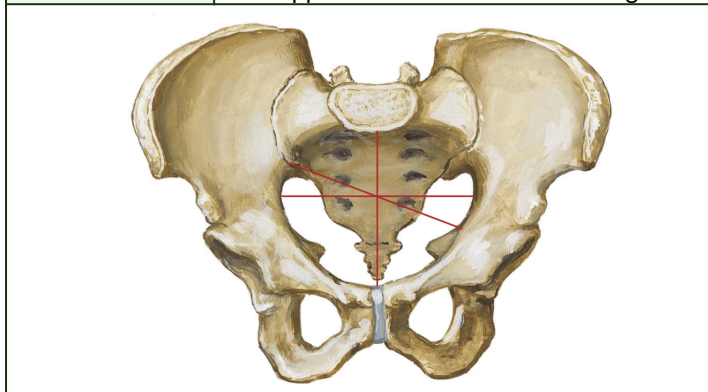
Blue: Book Reference - Snell/Netter's/Abraham

Red: Previous transes

Italicized: Verbatim emphasized from lecturer

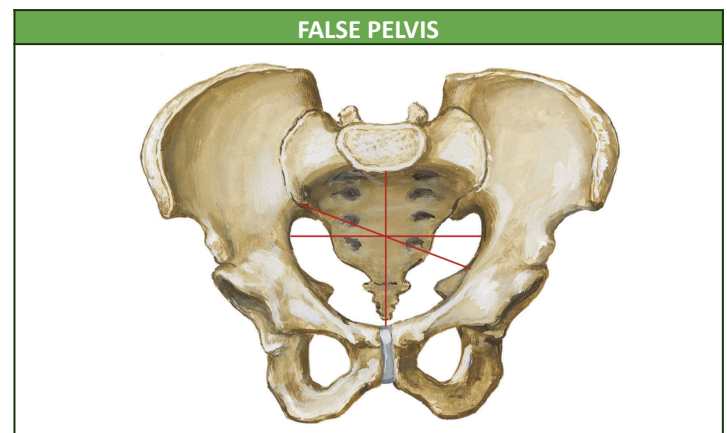


DEFINITION	<ul style="list-style-type: none"> Region of the trunk below the abdomen and meets the lower extremity Basin shaped and is more correctly applied to the skeleton of the region
-------------------	---

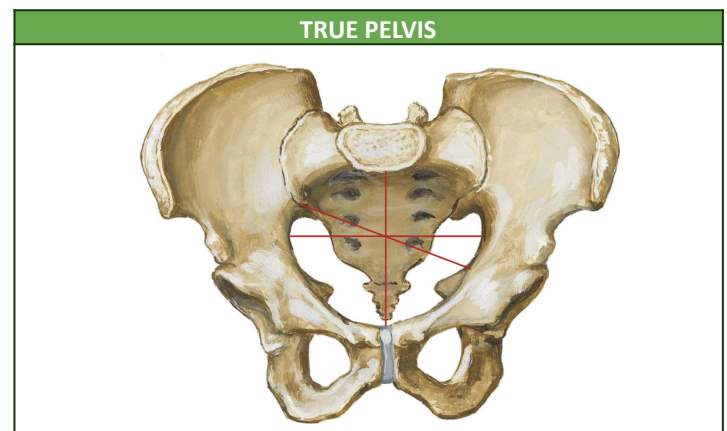


SURFACE LANDMARKS	<ul style="list-style-type: none"> Pubic tubercle: bony projection at the supero-lateral border of the body of the pubic bone Anterior superior iliac spine (ASIS) Posterior superior iliac crest (PSIS) Iliac crest Symphysis pubis <p>MNEMONIC: PAPIS</p>
--------------------------	---

COMPOSITION	<ul style="list-style-type: none"> 2 hip bones <ul style="list-style-type: none"> Articulates with the sacrum posteriorly. Unites in the symphysis pubis. Sacrum Coccyx
DIVISION	<ol style="list-style-type: none"> False or greater pelvis <ul style="list-style-type: none"> Extends from the iliac crest (superiorly) up to pelvic inlet (inferiorly). The pelvic inlet separates the false pelvis above from the true pelvis below. True or lesser pelvis <ul style="list-style-type: none"> Divided by the pelvic brim (pelvic inlet)

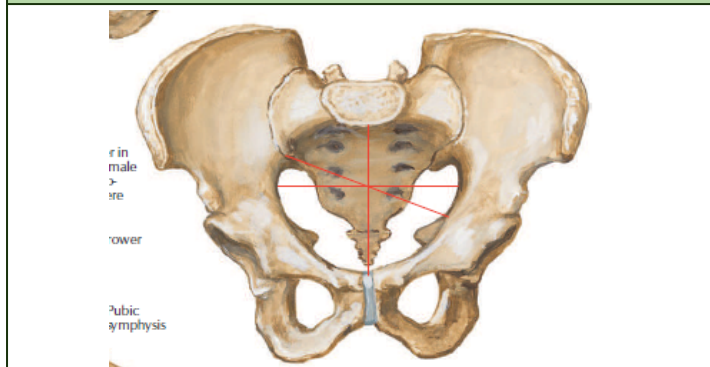


BOUNDARIES	<i>*If you look at the pelvic bone in the laboratory, you will notice that it is tilted slightly forward in order to visualize the boundaries.</i>
BEHIND	<ul style="list-style-type: none"> Lumbar vertebrae
LATERAL	<ul style="list-style-type: none"> Iliac fossa Iliacus muscle
FRONT	<ul style="list-style-type: none"> Anterior abdominal wall
SIGNIFICANCE	<ul style="list-style-type: none"> Little clinical significance (Snell) Considered part of abdominal cavity During early stages of labor, it helps guide the fetus into the true pelvis



DEFINITION	<ul style="list-style-type: none"> From the false pelvis, you enter the pelvic inlet and the cavity there is the true pelvis. The true pelvis is lesser or smaller in capacity compared to the false pelvis.
COMPOSITION	<ul style="list-style-type: none"> Has an inlet, outlet, and a cavity in both sexes.
SIGNIFICANCE	<ul style="list-style-type: none"> Forms the bony canal through which the child passes during birth.

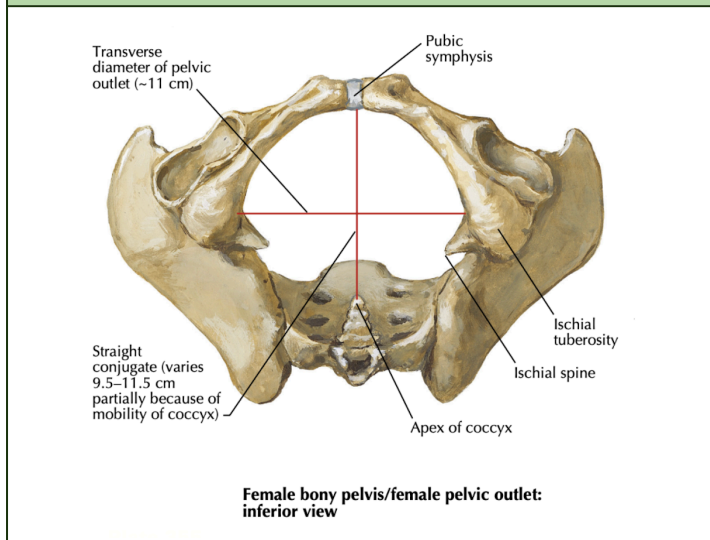
PELVIC INLET



Male pelvis/male pelvic inlet: anterior view

POSITION	BOUNDARIES
POSTERIOR	Boundaries: <ul style="list-style-type: none"> Sacral Promontory
LATERAL	<ul style="list-style-type: none"> Iliopectineal Line <ul style="list-style-type: none"> Crest formed by the edge of the ilium and pubic bone
MIDDLE	<ul style="list-style-type: none"> Symphysis Pubis

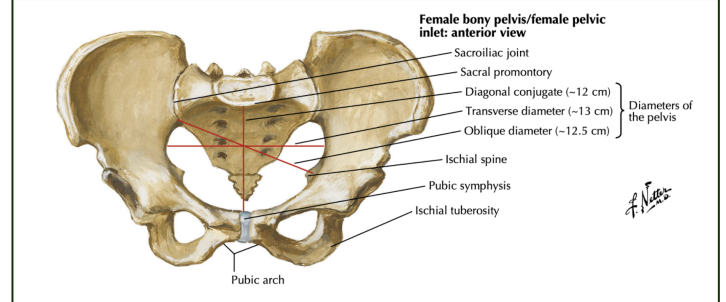
PELVIC OUTLET



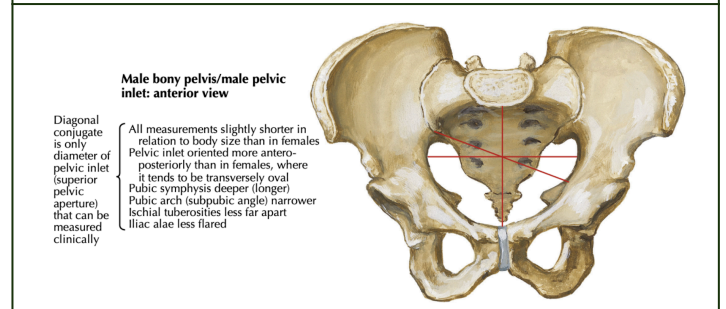
Female bony pelvis/female pelvic outlet: inferior view

DEFINITION	<ul style="list-style-type: none"> Seen inferiorly Diamond shaped
BOUNDARIES	Boundaries: <ul style="list-style-type: none"> Coccyx Ischial Tuberosities Pubic Arch <ul style="list-style-type: none"> Formed by the inferior rami of the pubic bone

PELVIS COMPARISON TABLE



Female bony pelvis/female pelvic inlet: anterior view

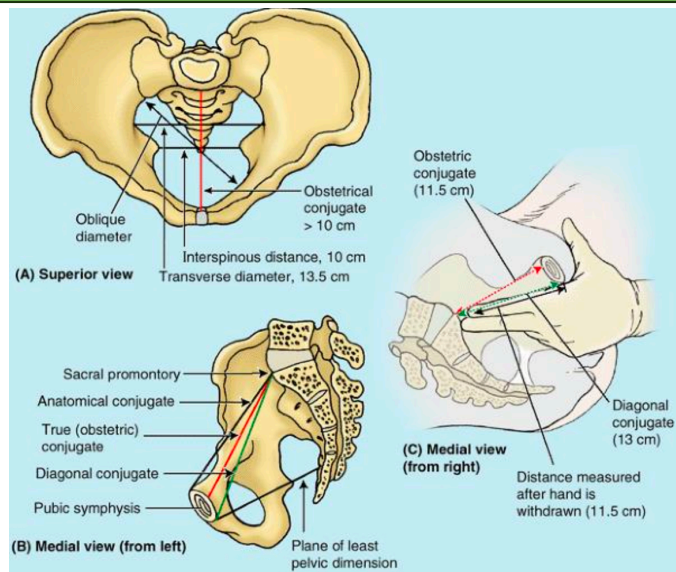


Male bony pelvis/male pelvic inlet: anterior view

	MALE	FEMALE
BONES	Heavier and Rougher	Lighter and Smoother
SACRUM	Narrower and more curved	Broader and less curved
GREATER SCIATIC NOTCH	Deeper and narrower	Shallower and wider
ILIAC FOSSA	Deeper	Shallower
ISCHIAL SPINE	More projecting	Less projecting (more wider distance between the two tips)
ISCHIAL TUBEROSITY	Inverted	Everted
SYMPHYSIS PUBIS	Longer	Shorter
SUBPUBIC ANGLE	Narrower and pointed	Wider and more rounded
SUPERIOR APERTURE (PELVIC INLET)	Heart shape	Oval shape <i>Other shape:</i> <ul style="list-style-type: none"> Anthropoid Gynecoid Platypelloid: generally more transversely oval, making it suitable for childbirth.
MAJOR PELVIS	Narrower	Wider
MINOR PELVIS (TRUE PELVIS)	Deeper and narrower	Shallower and wider

CAPACITY OF MINOR PELVIS	Less	Greater
		<i>Allows for the accommodation of pelvic viscera, such as the bladder and uterus.</i>

MEASUREMENTS OF TRUE PELVIS



TRUE CONJUGATE (OBSTETRICAL)	11.5 cm
DIAGONAL CONJUGATE	13 cm
INTERSPINOUS DISTANCE	10 cm

Note:

- Features of the female pelvis are more conducive to childbirth; hence, it is important to know certain measurements of the female pelvis
- **Anatomical conjugate**
 - Sagittal view:
 - Tip of the Symphysis Pubis
 - Sacral Promontory
 - **Cannot be measured clinically**
- **Diagonal conjugate**
 - Distance between the Inferior border of the Symphysis pubis and the Sacral promontory
 - Can be measured during internal examination
- These distances/measurements are important as they **approximate the diameter of the pelvic inlet**
- Compared against the **size of the fetal head**

COMPOSITION OF WALLS OF TRUE PELVIS OR PELVIC WALL

SUPPORTING FRAMEWORK	<ul style="list-style-type: none"> • Bones • Joints • Ligaments • Membranes • Lined within by muscles and are covered with fascia
PELVIC WALL	<ul style="list-style-type: none"> • 3 strata from outermost - inwards <ul style="list-style-type: none"> ○ Osteo-fibrous structures (bones & ligaments) ○ Muscular ○ Fascial

JOINTS

JOINTS	FEATURES	LOCATION
SACRO-COCCYGEAL JOINT	<ul style="list-style-type: none"> • Supported by 3 ligaments <ul style="list-style-type: none"> ○ Anterior ○ Lateral ○ Posterior 	<ul style="list-style-type: none"> • Between the sacrum and the coccyx
PUBIC SYMPHYSIS	<ul style="list-style-type: none"> • Junction where the two pubic bones meet. • Cartilaginous joint 	
SACRO-ILIAC JOINTS	<ul style="list-style-type: none"> • Synovial joint • There will be a movement here during parturition or child birth 	<ul style="list-style-type: none"> • Between sacrum and ilium
LUMBOSACRAL JOINTS	<ul style="list-style-type: none"> • Synovial joint 	<ul style="list-style-type: none"> • Between L5 & S1
COCCYGEAL JOINTS	<ul style="list-style-type: none"> • Fixed 4-5 coccygeal joints 	<ul style="list-style-type: none"> • Between the coccyx

LIGAMENTS

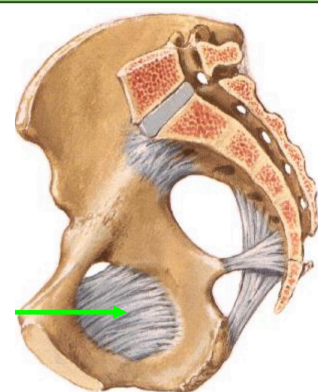
LIGAMENTS	FEATURES	
SACROTUBEROUS LIGAMENT	Attached from the ischial tuberosity to the sacrum	Converts sciatic notches into greater and lesser sciatic foramen
SACROSPINOUS LIGAMENT	Attached from the sacrum to the ischial spine	
ILIO LUMBAR LIGAMENT	Located between the transverse process of L5 and iliac crest	

Note:

- Importance of sciatic notch: structures pass through here
- Between the greater and lesser sciatic notch: **ischial spine**

MEMBRANES

OBTURATOR MEMBRANE

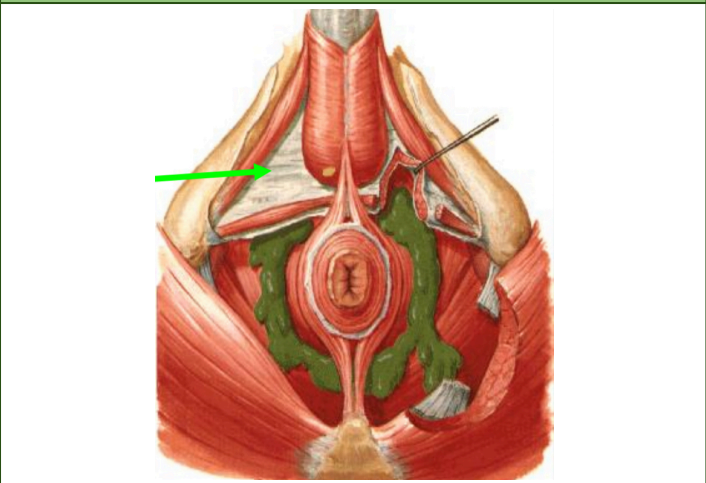


OBTURATOR MEMBRANE (GREEN ARROW)

FUNCTION	<ul style="list-style-type: none"> • Covers the obturator foramen • Almost completely close the opening except in the supero-anterior portion <ul style="list-style-type: none"> ○ The opening will lead to the obturator canal kaya not covered
-----------------	--

OBTURATOR CANAL	<ul style="list-style-type: none"> • A gap that is not covered • Important passageway for obturator vessels and nerves
------------------------	--

PERINEAL MEMBRANE

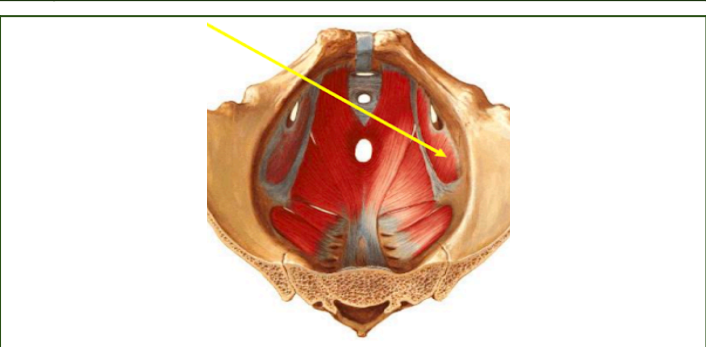


PERINEAL MEMBRANE (GREEN ARROW)

FEATURE	<ul style="list-style-type: none"> • It delineate the superficial perineal pouch from the deep perineal pouch
----------------	--

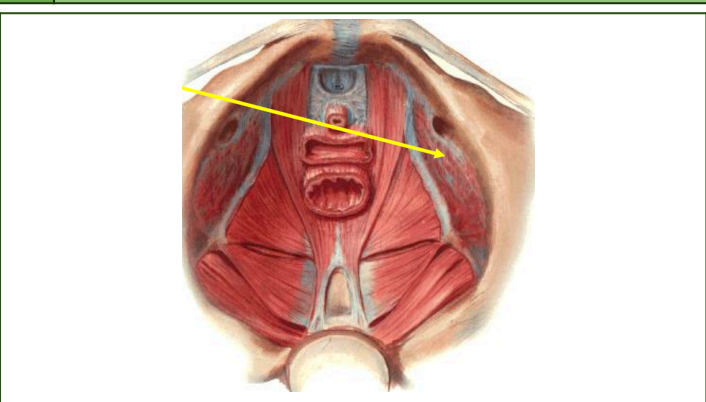
PELVIC MUSCLES

1 **OBTURATOR INTERNUS**



ORIGIN	<ul style="list-style-type: none"> • Obturator membrane and rim of obturator foramen
INSERTION	<ul style="list-style-type: none"> • Greater trochanter of femur
NERVE	<ul style="list-style-type: none"> • Nerve to obturator internus
ACTION	<ul style="list-style-type: none"> • Lateral rotator of femur and abducts it when the hip joint is flexed
NOTABLE CHARACTERISTICS	<ul style="list-style-type: none"> • Covers lateral wall of the pelvic cavity

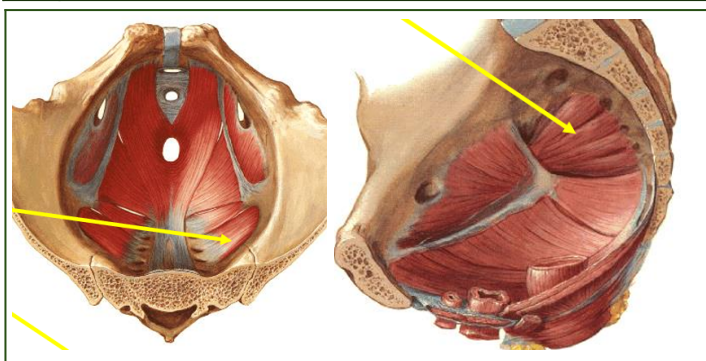
a **OBTURATOR FASCIA**



NOTABLE CHARACTERISTICS	<ul style="list-style-type: none"> • Lines the obturator internus • It fuses with periosteum superiorly except: <ul style="list-style-type: none"> ○ Areas of obturator canal
--------------------------------	---

	<ul style="list-style-type: none"> ○ Inferiorly where it thickens and forms <u>arcus tendinous</u>
	<ul style="list-style-type: none"> • Forms the sidewall of the ischio-rectal fossa. • Arcus tendinous serves as partial origin or attachment of the levator ani muscle • Obturator Fascia extends inferiorly beyond the level of pelvic diaphragm/floor of pelvic cavity • Obturator muscle will extend into the perineal region.

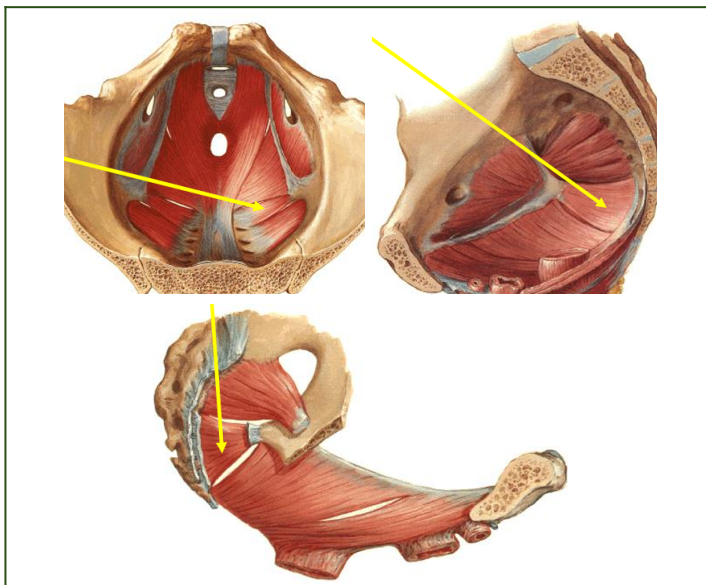
2 **PIRIFORMIS**



ORIGIN	<ul style="list-style-type: none"> • 2nd, 3rd, 4th sacrum • Passes thru greater sciatic foramen
INSERTION	<ul style="list-style-type: none"> • Greater trochanteric process of femur
NERVE	<ul style="list-style-type: none"> • 1st & 2nd sacral nerves
ACTION	<ul style="list-style-type: none"> • Same as obturator internus

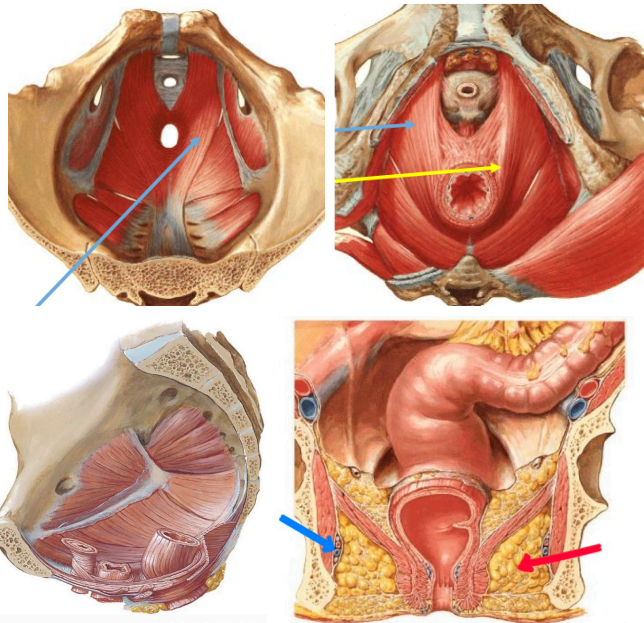
3 **PELVIC DIAPHRAGM**

a **COCCYGEUS**



ORIGIN	<ul style="list-style-type: none"> • Ischial spine
INSERTION	<ul style="list-style-type: none"> • Sacrum • Coccyx
NERVE	<ul style="list-style-type: none"> • Sacral Nerve
NOTABLE CHARACTERISTICS	<ul style="list-style-type: none"> • Less movement • Degenerates forming sacrospinous ligament

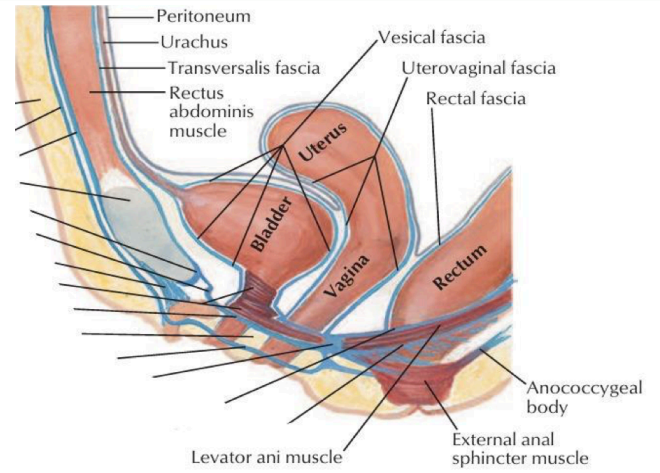
b LEVATOR ANI



(Coronal section of the pelvis)

FORMED BY 3 MUSCLES	<ul style="list-style-type: none"> • Iliococcygeus • Pubococcygeus (Top Left and Right Light Blue Arrows) • Puborectalis (Yellow Arrow)
ORIGIN	<ul style="list-style-type: none"> • Pubic bone • Obturator fascia (arcus tendinous) • Ischial spine
INSERTION	<ul style="list-style-type: none"> • Median rian raphe (anococcygeal ligament) • Coccyx • Anterior sacro-coccygeal ligament
NERVE SUPPLY	<ul style="list-style-type: none"> • Pelvic side: Lower sacral nerve • Perineal side: Inferior hemorrhoidal nerve
ACTION	<ul style="list-style-type: none"> • Muscular support of the pelvic viscera • Levator ani constricts the rectum and pulls it forward the puborectalis muscle and adds to its continence • Assist abdominal muscle to increase intra-abdominal pressure (during defecation, vomiting, and forceful respiration) • Female: sphincter vagina, important in parturition (support the head of the baby during expulsion efforts of the uterus and abdominal muscles)
ISCHIORECTAL SPACE (FOSSA) (RED ARROW)	<ul style="list-style-type: none"> • Wedge-shaped are below the levator ani • Contains adipose tissue, which can be infected and lead to Fournier's gangrene (extensive necrotizing infection around the anus)
ALCOCK'S CANAL (BLUE ARROW)	<ul style="list-style-type: none"> • Obturator internus muscle and fascia forms the side wall of the ischiorectal fossa. And in this side wall is where you can locate the alcock's canal, which contains: <ul style="list-style-type: none"> ○ Pudendal nerve ○ Internal pudendal vessels

PELVIC DIAPHRAGM IN SAGITTAL SECTION

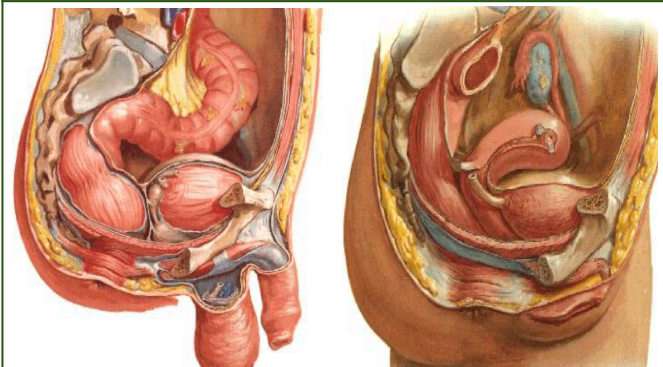


FEATURE	<ul style="list-style-type: none"> • Rectum posteriorly • Pelvic cavity - Anything superior or above the Levator ani muscle is • Perineum or perineal region - Everything below the Levator ani muscle
----------------	---

PELVIC CAVITY

ANTERIOR PELVIC WALL	<ul style="list-style-type: none"> • Pubic bone • Pubic rami • Symphysis pubis
POSTERIOR PELVIC WALL	<ul style="list-style-type: none"> • Sacrum and coccyx • Piriformis muscle • Parietal pelvic fascia
LATERAL PELVIC WALL	<ul style="list-style-type: none"> • Hip (innominate) bone below the pelvic inlet • Obturator internus muscle • Sacrotuberous and sacrospinous ligaments
INFERIOR PELVIC WALL (FLOOR)	<ul style="list-style-type: none"> • Pelvic diaphragm <ul style="list-style-type: none"> ○ Divides the pelvic cavity (above) from the perineum (below) ○ Consists of: coccygeus and levator ani

PELVIC PERITONEUM



Male Pelvis

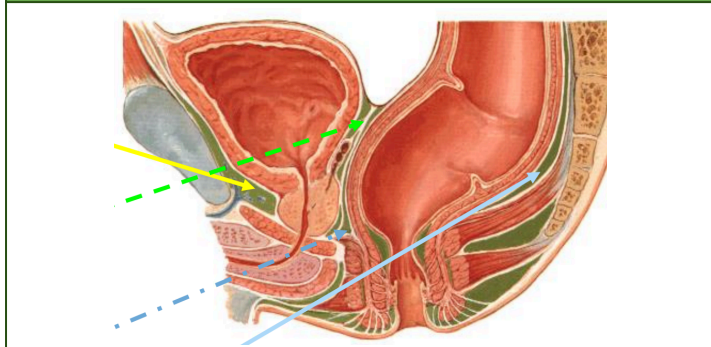
Female Pelvis

MALE	<ul style="list-style-type: none"> • Urinary bladder • Rectum
FEMALE	<ul style="list-style-type: none"> • Urinary bladder • Uterus: in between bladder and rectum • Rectum • Vaginal canal
FEATURE	<ul style="list-style-type: none"> • The true pelvis

	<ul style="list-style-type: none"> ○ Basically one compartment, but when there are visceral organs inside, we divide it into smaller spaces (pelvic spaces) in between visceral organs ● Rectum is only lined by peritoneum at the upper $\frac{1}{3}$ until the anterior lateral but the middle 3rd only has the front. Then for the most distal $\frac{1}{3}$ has no peritoneal lining
NOTABLE PELVIC SPACES	<ul style="list-style-type: none"> ● Retropubic space: at the back of the pubic bone ● Retrovesical space: at the back of urinary bladder but in front of the rectum ● Prerectal space: in front of rectum but near the prostate

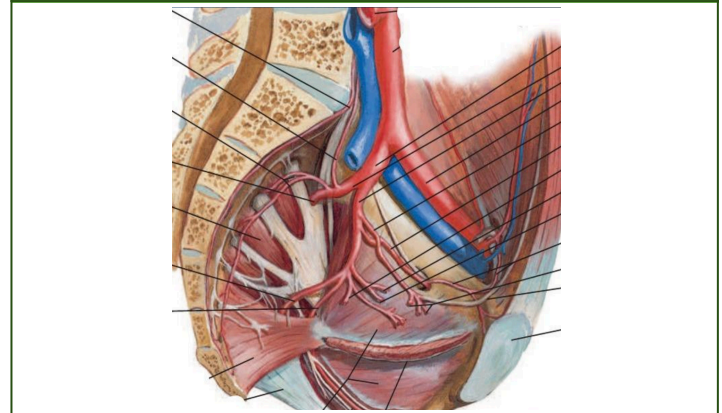
FEMALE PELVIC SPACE	<ul style="list-style-type: none"> ● Rectum posteriorly ● Urinary bladder anteriorly ● The deepest depression in the female cavity is the Rectouterine pouch (Pouch of Douglas)

PELVIC SPACES

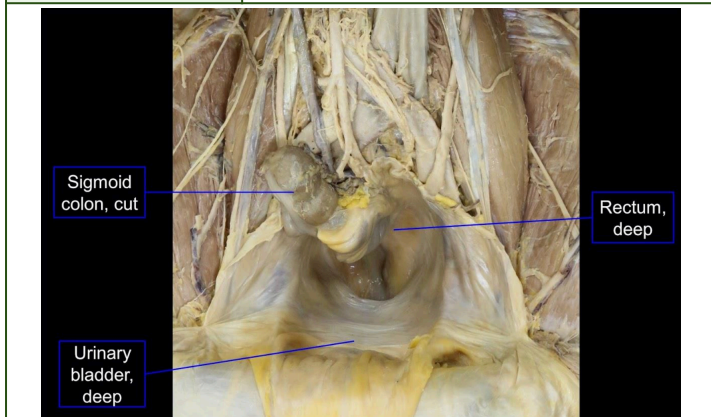


DESCRIPTION	<ul style="list-style-type: none"> ● Before/In front of the Sacrum ● Behind the Rectum
STRUCTURES INCLUDED	<ul style="list-style-type: none"> ● Blood vessels ● Nerves ● Plexuses ● Pelvic Peritoneal cavity ● Retropubic space (Retzius space) (Yellow Arrow) ● Retrovesical space (Green Arrow) ● Prerectal space (Dashed Blue Arrow) ● Presacral space (Light Blue Arrow)
CLINICAL SIGNIFICANCE	<ul style="list-style-type: none"> ● When dissecting tumors in the rectum, this space is strictly identified to avoid damaging the structures found here

NEUROVASCULAR STRUCTURE IN THE PELVIC CAVITY
INTERNAL ILLIAC ARTERY

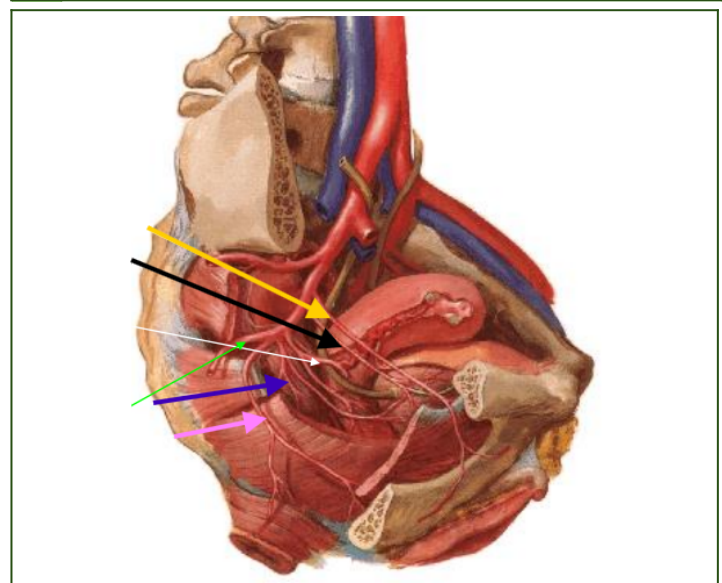


DESCRIPTION	<ul style="list-style-type: none"> ● Most, if not all of blood vessels that goes into the pelvic cavity comes from this artery ● Most of the time, you cannot see the divisions of the iliac artery in the cadaver, instead you will see the branches already.
--------------------	--



MALE PELVIC SPACE	<ul style="list-style-type: none"> ● Rectum posteriorly ● Urinary bladder anteriorly
--------------------------	--

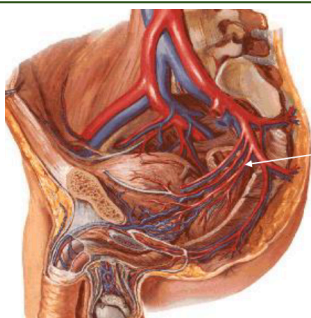
ANTERIOR DIVISION OF INTERNAL ILIAC ARTERY
I ANTERIOR DIVISION (FEMALE)



DESCRIPTION	<ul style="list-style-type: none"> ● Arteries can either: <ul style="list-style-type: none"> ○ Go into the visceral organs
--------------------	---

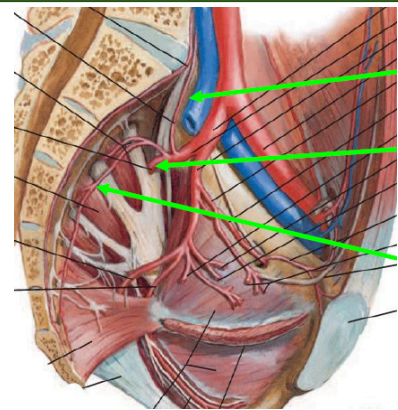
	<ul style="list-style-type: none"> ○ Out of pelvic cavity
BRANCHES	<ul style="list-style-type: none"> ● Obturator a. (Yellow Arrow) ● Umbilical a. (Black Arrow) <ul style="list-style-type: none"> ○ Superior vesical a ● Uterine a. (White Arrow) <ul style="list-style-type: none"> ○ Vaginal a. (inferior vesical a in male) ● Middle rectal a. (Blue Arrow) ● Internal pudendal a. (Pink Arrow) ● Inferior gluteal a. (Green Arrow)
OBTURATOR ARTERY (YELLOW ARROW)	<ul style="list-style-type: none"> ● From its origin it goes to the lateral wall of the pelvis and exits in the obturator canal ● Will branch out into the medial thighs and into the acetabulum ● In 20-25% of individuals, the obturator artery originates from the inferior epigastric artery instead of internal iliac artery, but still enters the obturator foramen
UMBILICAL ARTERY (BLACK ARROW)	<ul style="list-style-type: none"> ● From its origin, while still inside the pelvic cavity, the umbilical artery is open and will give rise to its branch, the superior vesical artery, that proceeds into the urinary bladder ● When in the abdominal wall, it will be obliterated to form the medial umbilical ligament
UTERINE ARTERY (WHITE ARROW)	<ul style="list-style-type: none"> ● Branches into vaginal artery ● Sometimes the vaginal artery can arise directly from the internal iliac, but most of the time it comes from the uterine artery ● VAGINAL ARTERY = ABSENT IN THE MALE ● Male counterpart = inferior vesical artery
MIDDLE RECTAL ARTERY (BLUE ARROW)	<ul style="list-style-type: none"> ● Going to the middle third of the rectum
INTERNAL PUDENDAL ARTERY (PINK ARROW)	<ul style="list-style-type: none"> ● Exits the pelvic cavity via the greater sciatic foramen ● Enters the perineum via the lesser sciatic foramen ● Supplies the perineum
INFERIOR GLUTEAL ARTERY (GREEN ARROW)	<ul style="list-style-type: none"> ● Exits the pelvic cavity via the greater sciatic foramen at the lower border of the piriformis ● Emerges in the gluteal region ● Supplies the gluteus maximus muscle

II ANTERIOR DIVISION (MALE)



DESCRIPTION	<ul style="list-style-type: none"> ● Same group of arteries except for additional inferior vesical artery ● Arteries: <ul style="list-style-type: none"> ○ Obturator artery ○ Umbilical artery ○ Inferior vesical artery (White Arrow) ○ Superior vesical artery ○ Middle rectal artery ○ Internal pudendal artery ○ Inferior gluteal artery
SUPERIOR VESICAL ARTERY	<ul style="list-style-type: none"> ● Arises from the proximal patent part of the umbilical artery ● Supplies the upper portion of the bladder ● Gives off the artery to the vas deferens
INFERIOR VESICAL ARTERY	<ul style="list-style-type: none"> ● Supplies the base of the bladder and the prostate and seminal vesicles in the male

POSTERIOR DIVISION OF INTERNAL ILIAC ARTERY



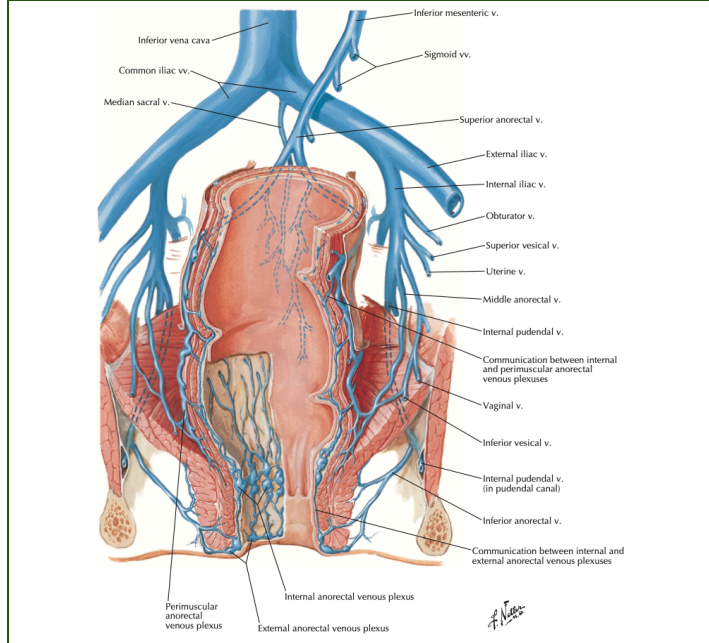
DESCRIPTION	<ul style="list-style-type: none"> ● Composed of 3 branches (<i>from uppermost to lowermost in the photo above</i>) <ul style="list-style-type: none"> ○ Iliolumbar (Top Green Arrow) ○ Lateral sacral arteries (Middle Green Arrow) ○ Superior gluteal artery (Bottom Green Arrow)
ILIOLUMBAR ARTERY	<ul style="list-style-type: none"> ● Goes upward from posterior division along the lumbosacral area of the vertebra ● Gives off branch to iliacus muscles
SUPERIOR GLUTEAL ARTERY	<ul style="list-style-type: none"> ● Exits via greater sciatic foramen in the superior border of the piriformis ● Emerges in the gluteal region
LATERAL SACRAL ARTERY	<ul style="list-style-type: none"> ● Courses in the anterior surface of the sacrum ● Penetrates the sacral foramina ● Supplies the structures in the perineal area

OTHER BLOOD VESSELS OF PELVIS THAT DO NOT ARISE FROM THE INTERNAL ILIAC

OVARIAN ARTERY	<ul style="list-style-type: none"> ● Emerging directly from the abdominal aorta, left and right side
SUPERIOR RECTAL ARTERY	<ul style="list-style-type: none"> ● Originates from the inferior mesenteric artery

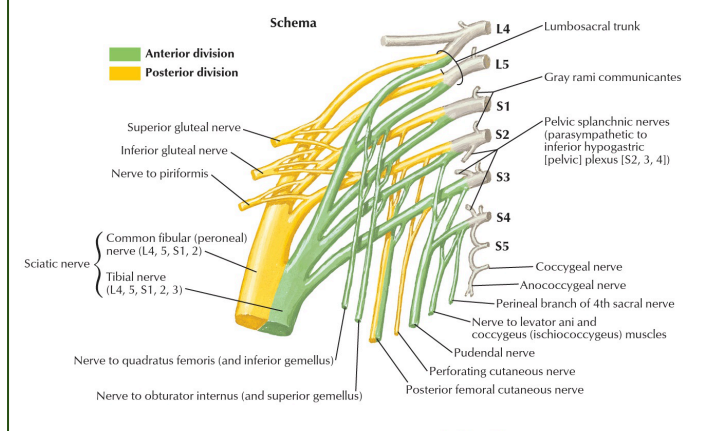
MEDIAN SACRAL ARTERY	<ul style="list-style-type: none"> • Bifurcation of the abdominal aorta
-----------------------------	--

PELVIC VEINS



DESCRIPTION	<ul style="list-style-type: none"> • All pelvic arteries that enter the pelvic cavity has its vein counterpart except umbilical artery • Some of the veins will drain to the systemic circulation
INTERNAL PUDENDAL VEIN	<ul style="list-style-type: none"> • Drains into the internal iliac → drains into the common iliac → drains into Inferior vena cava
SUPERIOR HEMORRHODIAL VEIN	<ul style="list-style-type: none"> • Does not drain to the systemic • Drains into the inferior mesenteric → unites with the splenic → unites with the superior mesenteric vein → portal vein → Liver

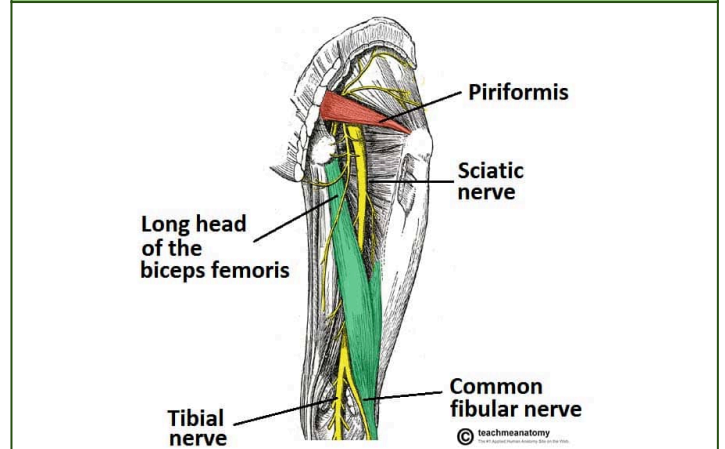
NERVES IN PELVIC CAVITY



SACRAL PLEXUS	<ul style="list-style-type: none"> • Nerves that emerge at the level of the pelvic cavity • Comes from the sacral spinal nerve from the sacral region of the spinal chord • Including the L4-L5 spinal nerve turns it into the sacrolumbar plexus • The largest nerve that will emerge from the lumbosacral plexus is the Sciatic Nerve
SCIATIC NERVE	<ul style="list-style-type: none"> • Divided into two:

(L4 -L5 , S1-S3)	<ul style="list-style-type: none"> ○ Common Peroneal Nerve ○ Tibial Nerve • Supplies the posterior thigh and posterior leg
POSTERIOR FEMORAL CUTANEOUS NERVE (S1-S3)	<ul style="list-style-type: none"> • Lies beside the Sciatic nerve • Goes to the skin in the posterior side of the thigh

SCIATIC NERVE



DESCRIPTION	<ul style="list-style-type: none"> • It supplies most muscles of the posterior thigh, leg, and foot. • It is formed from L4–S3 nerve roots.
SCIATIC NERVE EXIT	<ul style="list-style-type: none"> • The sciatic nerve exits the pelvis through the greater sciatic foramen, below the piriformis muscle.
LOCATION IN GLUTEAL REGION	<ul style="list-style-type: none"> • In the gluteal region, the sciatic nerve lies inferior to the piriformis muscle.

POSTERIOR DIVISION OF NERVES IN PELVIC CAVITY

BRANCHES	DESCRIPTION
Superior Gluteal Nerve	<ul style="list-style-type: none"> • L4-L5; S1 • Innervates gluteus medius, gluteus minimus, tensor fascia latae • Exits via greater sciatic foramen above piriformis
Inferior Gluteal Nerve	<ul style="list-style-type: none"> • L4-L5; S2 • Innervates gluteus maximus
Piriformis Nerve	<ul style="list-style-type: none"> • S1-S2
Perforating Cutaneous Nerve	<ul style="list-style-type: none"> • S2-S3

ANTERIOR DIVISION OF NERVES IN PELVIC CAVITY

BRANCHES	DESCRIPTION
N. quadratus femoris & Inferior Gemellus	<ul style="list-style-type: none"> • L4-L5; S1
N. Obturator internus & Superior Gemellus	<ul style="list-style-type: none"> • L4-L5; S2
Pudendal Nerve	<ul style="list-style-type: none"> • S2-S4

N. levator ani & coccygeus	● S3-S4
Perineal nerve	● S4

PUDENDAL NERVE (CHIEF NERVE OF THE PERINEUM)	
FEATURE	DESCRIPTION
MAIN FUNCTION	● Chief somatic nerve of the perineum
TYPE OF FIBERS	● Both motor and sensory
SUPPLIES	● Perineal muscles, external genitalia, external urethral and anal sphincters
SPINAL SROOT	● S2-S4

COURSE OF THE PUDENDAL NERVE	
STEP	DESCRIPTION
1	● Originates in the pelvic cavity
2	● Exits via greater sciatic foramen (below piriformis)
3	● Curves around ischial spine
4	● Enters the perineum via lesser sciatic foramen
5	● Travels with the internal pudendal artery
6	● Supplies the perineal region

NERVE TO LEVATOR ANI

ORIGIN	● Sacral plexus (S3-S4)
COURSE	● Enters pelvis directly
FUNCTION	● Supplies levator ani muscles
EXIT	● Does not pass through sciatic foramina

QUESTIONS

Which nerve innervates uterus, bladder, and rectum (visceral organs)?
Answer: None of the somatic nerves listed
Reason: Pelvic visceral organs are controlled by autonomic nerves
 (sympathetic and parasympathetic fibers)

Note:

- **Autonomic supply:**
 - **Pelvic splanchnic nerves (parasympathetic)**
 - **Inferior hypogastric plexus**

SUPERIOR HYPOGASTRIC PLEXUS OF NERVES

AUTONOMIC NERVE FIBERS

- Contain sympathetic nerve fibers to form sympathetic chain of ganglia
- Thoracolumbar distribution
- Post ganglionic fibers forms the superior hypogastric plexus
 - Continuation of aortic plexus
- Splits to left and right hypogastric nerves
- When it descends S2-4 merges to form **pelvic-splanchnic nerve** (only parasympathetic fibers)

INFERIOR HYPOGASTRIC PLEXUS OF NERVES

- Which sphincter is under voluntary control? - **(sphincter urethrae)**
 - **Sphincter urethrae** - skeletal muscle at the level of diaphragm
 - **Sphincter vesicae** - smooth muscle
 - The contraction of the bladder would overcome the internal sphincter.

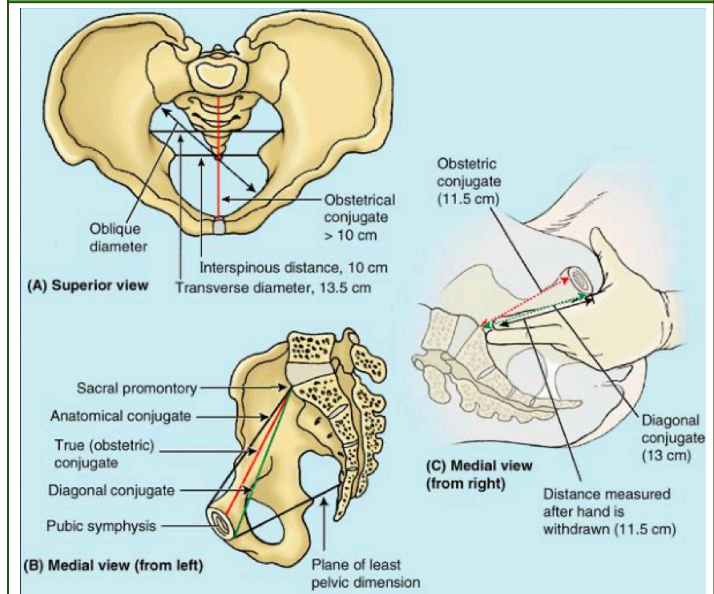
Summary table (see more in p. 12)

	GREATER SCIATIC FORAMEN	LESSER SCIATIC FORAMEN
MUSCLES	<ul style="list-style-type: none"> ● Piriformis 	<ul style="list-style-type: none"> ● Obturator Internus
VASCULATURE	<ul style="list-style-type: none"> ● *Superior Gluteal a.v. ● Inferior Gluteal a.v. ● Internal Pudendal a.v. 	<ul style="list-style-type: none"> ● Internal Pudendal a.v.
NERVES	<ul style="list-style-type: none"> ● *Superior Gluteal nerve ● Inferior Gluteal nerve ● Sciatic nerve ● Pudendal nerve ● Nerve to Obturator Internus ● Posterior Femoral Cutaneous ● Nerve to Quadratus Femoris 	<ul style="list-style-type: none"> ● Pudendal nerve ● Nerve to Obturator Internus
<p>Note:</p> <ul style="list-style-type: none"> ● * Pass through the greater sciatic foramen and the superior border of piriformis ● Yellow : passes through both foramen 		

	<p>to the sacral promontory, pwede mo ma-reach using your fingers.</p> <ul style="list-style-type: none"> ○ Now, if you estimate the size of the biparietal diameter of the pubis head then you will know if the mother can give birth via vaginal route.
X-RAY PELVIMETRY	<ul style="list-style-type: none"> ● Used to take the actual antero-posterior diameter or anatomic conjugate. ● You take an x-ray of the abdomen of the mother na manganganak na. Doon makikita mo na ang pubic bone and skull ng baby. You can measure the biparietal diameter. ● As the baby descends the birth canal, it will undergo 7 cardinal movements bago sya lumabas sa introitus. ● So it's very important to know the diagonal conjugate or the diameter of the pelvic inlet. Otherwise, if maliit ang pelvic inlet for the size of the baby, (eg. malaki ang baby/malaki ang tyan ng mother = large for gestational age (LGA)) baka di sya makadaan sa pelvic inlet, so meron kang cephalopelvic disproportion. Hindi magkamatch ang head ng baby sa pelvic inlet. You have to do other means of delivering the baby by cesarian section. This is just one factor that you will consider pagnagCS.

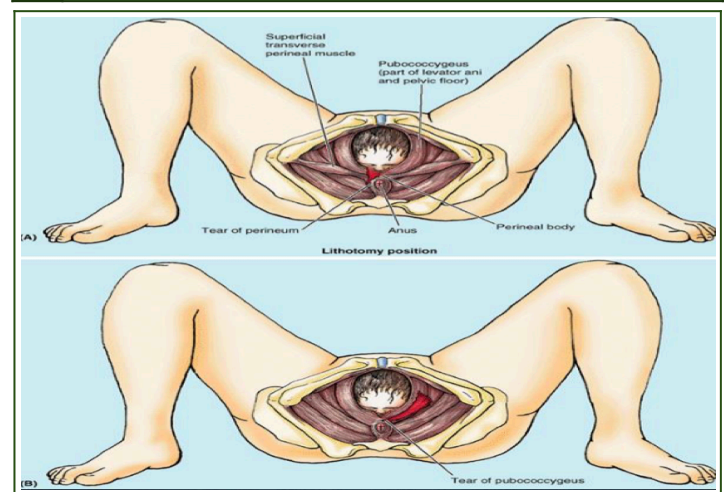
CLINICAL CORRELATIONS

PELVIC BONE



IMPORTANT MEASUREMENTS	<ul style="list-style-type: none"> ● Antero-posterior diameter of the pelvic inlet: <ul style="list-style-type: none"> ○ Distance between the symphysis pubis to the sacral promontory ○ Hindi mo masusukat yung actual diameter sa clinic. What you can measure is the diagonal conjugate. When you do the internal examination, from the inferior border of symphysis pubis
-------------------------------	--

1 TEAR OF PERINEAL MUSCLE



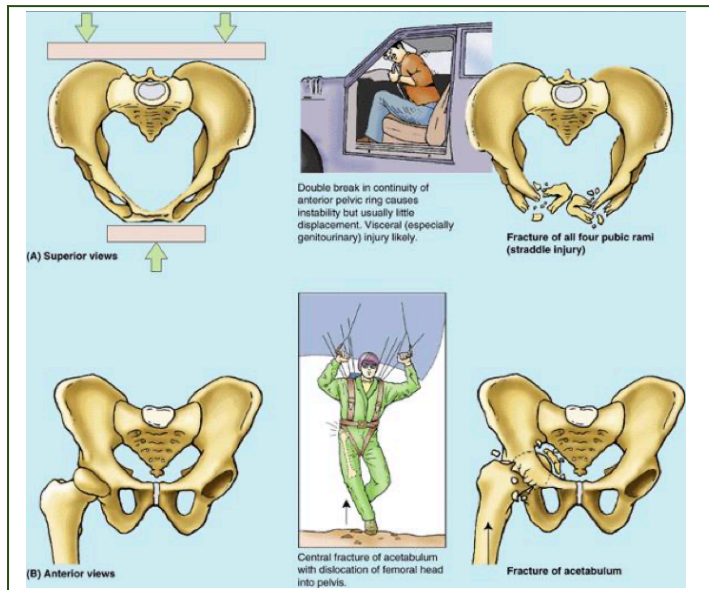
DESCRIPTION	<ul style="list-style-type: none"> ● Even if the baby's head can pass through the pelvic inlet and the pelvic outlet, minsan pagdating sa perineum masyadong tight pa yung perineal muscle lalo na yung primigravida (first baby/delivery through the vaginal route). If the perineal muscle will not relax or stretch, this injury happens, including the perineal wall muscle (tear of perineal muscle). ● Hematoma in the puborectalis muscle may also happen if the baby passes
--------------------	---

	through the perineum na hindi pa nakakstretch masyado yung muscle fibers.
PREVENTION	<ul style="list-style-type: none"> ● Episiotomy - making a cut sa perineal muscle to widen the perineal area in order to prevent the inadvertent injury to the perineal muscle wall pagexit ng baby through the vaginal route ● Making an episiotomy is better than lacerating the muscle all around. Yung pinilit mong lumabas ang head ng baby without making an episiotomy. Kasi if you do an episiotomy, it's like a controlled cut or incision. Na paglumabas ang baby pwedeng marepair yun kesa may cut sya sa several points ng perineum. You do this with anesthesia.

muscle attached to that, like the sartorius.

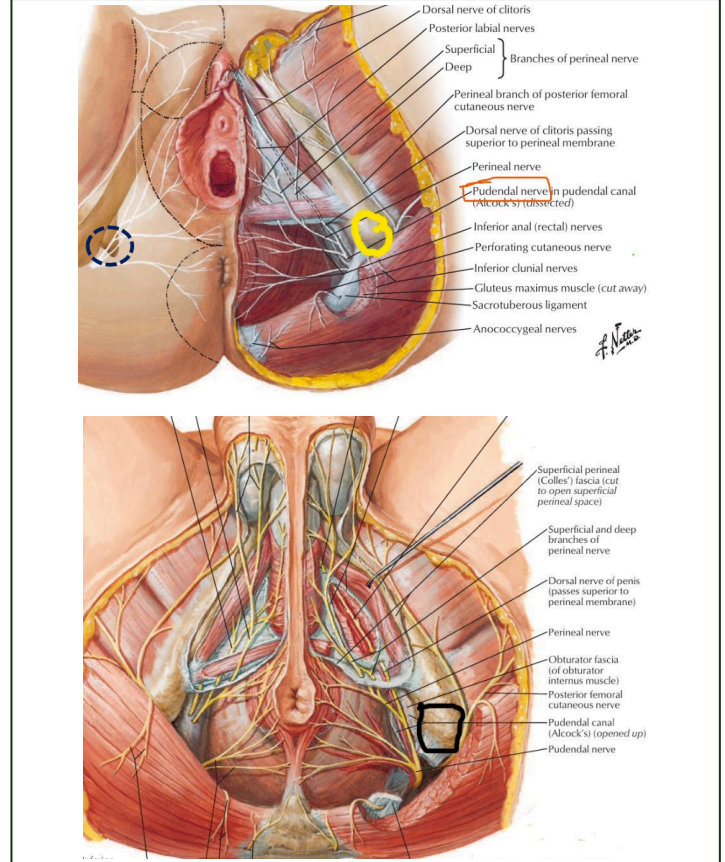
- Note:**
- Sartorius originates in the ASIS
 - Rectus femoris originates in the AIIS
 - Hamstring muscles originates in the ischial tuberosity

2 FRACTURES



VEHICULAR ACCIDENT FRACTURE	<ul style="list-style-type: none"> ● The pubic bone is pressed against the dashboard. And when you fracture the pubic bone, the urinary bladder will be affected and there will be blood in the urine, called hematuria.
ONE-SIDED FRACTURE OF THE PELVIS	<ul style="list-style-type: none"> ● Superior rami ● Anterior rami
TWO-SIDED FRACTURE OF THE PELVIS	<ul style="list-style-type: none"> ● Instability of the pelvis because it will be disconnected from the rest of the pelvic bone. The supination of the sacroiliac joint will happen.
ISOLATED FRACTURE	<ul style="list-style-type: none"> ● For example, anterior-superior iliac spine lang. Pag nafracture mo yan, you will affect the function of the

PUDENDAL NERVE



DESCRIPTION

- Chief nerve supply of the perineum
- It supplies the motor in the genital organs and the sensory
- This is **where we anesthetize before episiotomy to block the nerve**

LANDMARK

- Ischial spine
- Can be palpated through internal examination
- Double backs from the greater sciatic foramen to lesser sciatic foramen to perineum. In between the two foramens is the ischial spine.
 - o You can inject your anesthetic anywhere inferior and slightly medial
 - o You do not have to hit the nerve, you can hit the area around it

!! HARD SUMMARY !!

PELVIS		
SURFACE LANDMARKS	Pubic tubercle Anterior superior iliac spine (ASIS) Posterior superior iliac crest (PSIS) Iliac crest Symphysis pubis	
DIVISIONS	FALSE/GREATER/MINOR	TRUE/LESSER/MAJOR
	"Above the brim" <ul style="list-style-type: none"> • Lumbar vertebra • Iliac fossa and iliacus • Anterior abdominal wall 	"Below the brim" <ul style="list-style-type: none"> • Pelvic Brim • Pelvic Inlet • Pelvic Outlet
MEMBRANES	Obturator membrane Perineal membrane	
PELVIC MUSCLES	Obturator internus Piriformis Pelvic Diaphragm: <ul style="list-style-type: none"> • Coccygeus • Levator ani <ul style="list-style-type: none"> ○ Iliococcygeous ○ Pubococcygeous ○ Puborectalis 	
PELVIC WALL COMPOSITION	<ul style="list-style-type: none"> • Bones • Joints • Ligaments • Membranes 3 STRATA <ul style="list-style-type: none"> • Fascial • Osteofibrous • Muscular 	
PELVIC SPACES	RETROPUBIC	• Back of pubic bone
	RETROVESICAL	• Back of urinary bladder • In front of rectum
	PRERECTAL	• In front of rectum • Near prostate
	MALE PELVIC SPACE	• Posterior: Rectum • Anterior: Urinary Bladder
	FEMALE PELVIC SPACE	• Posterior: Rectum • Anterior: Urinary Bladder • Deepest Depression: Pouch of Douglas (Rectouterine Pouch)

PELVIS MOINA				
MUSCLE	ORIGIN	INSERTION	NERVE SUPPLY	ACTION
OBTURATOR INTERNUS	Obturator membrane and rim of obturator foramen	Greater trochanter of femur	Nerve to obturator internus	Lateral rotator of femur and abducts it when the hip joint is flexed
PIRIFORMIS	<ul style="list-style-type: none"> • 2nd, 3rd, 4th sacrum • Passes thru greater sciatic foramen 	Greater trochanteric process of femur	1st & 2nd sacral nerves	Same as obturator internus
PELVIC DIAPHRAGM				
COCCYGEUS	Ischial spine	Sacrum & Coccyx	Sacral Nerve	Assists levator ani to support the pelvic viscera; flexes coccyx
LEVATOR ANI Formed by Iliococcygeus Pubococcygeus Puborectalis	Pubic bone Obturator fascia Ischial spine	<ul style="list-style-type: none"> • Median radian raphe • Coccyx 	Pelvic side: Lower sacral nerve Perineal side: Inferior hemorrhoidal nerve	<ul style="list-style-type: none"> • Muscular support of the pelvic viscera • Female: sphincter to the anorectal

		<ul style="list-style-type: none"> Anterior sacro-coccygeal ligament 		junction and vagina
--	--	---	--	---------------------

PELVIC CAVITY	
ANTERIOR	<ul style="list-style-type: none"> Pubic bone Pubic rami Symphysis pubis
POSTERIOR	<ul style="list-style-type: none"> Sacrum and coccyx Piriformis muscle Parietal pelvic fascia
LATERAL	<ul style="list-style-type: none"> Hip (innominate) bone below the pelvic inlet Obturator internus muscle Sacro-tuberous and sacrospinous ligaments
INFERIOR (FLOOR)	<ul style="list-style-type: none"> Pelvic diaphragm

PELVIS COMPARISON TABLE		
	MALE	FEMALE
BONES	Heavier and rougher	Lighter and smoother
SACRUM	Narrower and more curved	Broader and less curved
GREATER SCIATIC NOTCH	Deeper and narrower	Shallower and wider
ILIAC FOSSA	Deeper	Shallower
ISCHIAL SPINE	More projecting	Less projecting (more wider distance between the two tips)
ISCHIAL TUBEROSITY	Inverted	Everted
SYMPHYSIS PUBIS	Longer	Shorter
SUBPUBIC ANGLE	Narrower and pointed	Wider and more rounded
SUPERIOR APERTURE (PELVIC INLET)	Heart shape	Oval shape
MAJOR PELVIS	Narrower	Wider
MINOR PELVIS (TRUE PELVIS)	Deeper and narrower	Shallower and wider
CAPACITY OF MINOR PELVIS	Less	Greater

NEUROVASCULAR STRUCTURES		
STRUCTURE	HIGH YIELD NOTES	ORIGIN BRANCH
INTERNAL ILIAC ARTERY	Supplies visceral organs and wall of pelvic cavity	Branch of Common Iliac Artery
OVARIAN ARTERY		Branch of abdominal aorta, left and right side
SUPERIOR RECTAL ARTERY		Branch of inferior mesenteric artery
MEDIAN SACRAL ARTERY	Bifurcation of the abdominal aorta	
PELVIC VEINS	Has the same corresponding arteries EXCEPT UMBILICAL ARTERY	
INTERNAL PUDENDAL	Drains into inferior vena cava	
SUPERIOR HEMORRHOIDAL VEIN	Does not drain into systemic	
SACRAL VEINS	Small veins prone to injury when removing rectum	

SACRAL PLEXUS	<ul style="list-style-type: none"> ● Sciatic Nerve (L4-L5, S1-S3) <ul style="list-style-type: none"> ○ Common peroneal nerve ○ Tibial nerve ● Posterior Femoral Cutaneous Nerve (S1-S3) ● Largest nerve of sacral plexus: sciatic nerve 	
----------------------	--	--

INTERNAL ILIAC ARTERY	
DIVISION	BRANCHES
ANTERIOR DIVISION (FEMALE)	<ul style="list-style-type: none"> ● Obturator artery ● Umbilical artery -> Superior vesical artery ● Uterine artery -> Vaginal artery ● Middle rectal artery <p>Terminal Branches:</p> <ul style="list-style-type: none"> ● Internal pudendal artery ● Inferior gluteal artery
ANTERIOR DIVISION (MALE)	<ul style="list-style-type: none"> ● Obturator artery ● Umbilical artery ● Uterine artery -> Inferior vesical artery ● Superior vesical artery ● Middle rectal artery <p>Terminal Branches:</p> <ul style="list-style-type: none"> ● Internal pudendal artery ● Inferior gluteal artery
POSTERIOR DIVISION	<ul style="list-style-type: none"> ● Iliolumbar artery ● Superior gluteal artery ● Lateral sacral artery

SACRAL PLEXUS	
	BRANCHES
POSTERIOR DIVISION	<ul style="list-style-type: none"> ● Superior gluteal nerve (L4-L5;S1) ● Inferior gluteal nerve (L5;S1-S2) ● Piriformis nerve (S1-S2) ● Perforating cutaneous nerve (S2-S3)
ANTERIOR DIVISION	<ul style="list-style-type: none"> ● N. quadratus femoris & inferior gemellus (L4-L5;S1) ● N. obturator internus & superior gemellus (L5;S1-S2) ● Pudendal nerve (S2-S4) ● N. levator ani & coccygeus (S3-S4) ● Perineal nerve (S4)

Summary table provided by Doc

	GREATER SCIATIC FORAMEN	LESSER SCIATIC FORAMEN
MUSCLES	<ul style="list-style-type: none"> ● Piriformis 	<ul style="list-style-type: none"> ● Obturator Internus
VASCULATURE	<ul style="list-style-type: none"> ● *Superior Gluteal a.v. ● Inferior Gluteal a.v. ● Internal Pudendal a.v. 	<ul style="list-style-type: none"> ● Internal Pudendal a.v.
NERVES	<ul style="list-style-type: none"> ● *Superior Gluteal nerve ● Inferior Gluteal nerve ● Sciatic nerve ● Pudendal nerve ● Nerve to Obturator Internus ● Posterior Femoral Cutaneous ● Nerve to Quadratus Femoris 	<ul style="list-style-type: none"> ● Pudendal nerve ● Nerve to Obturator Internus

* Pass through the greater sciatic foramen and the superior border of piriformis

Yellow – passes through both foramen

Legend:

Blue: Book Reference - Snell/Netter's/Abraham

Red: Previous transes

