ENT - THROAT

DISEASES OF THE NASOPHARYNX

- Surgical anatomy and physiology of nasopharynx
- Nasopharyngeal carcinoma
  - Diagnosis and management
- Adenoid
  - Diagnosis and management
- Juvenile angiofibroma
  - Diagnosis and management.

DISEASES OF THE PHARYNX

- Surgical anatomy and physiology of oral cavity, oropharynx, tonsil, Waldeyer's ring
- Anatomy of retropharyngeal and parapharyngeal spaces
- Physiology of mastication
- Diseases of the tonsils
  - Acute and chronic tonsillitis
    - Diagnosis and management
  - Vincent's angina
    - Diagnosis and management
  - Diphtheritic tonsillitis
    - Diagnosis and management
- Neck space infections and abscess
  - Retropharyngeal abscess, parapharyngeal abscess, peritonsillar abscess, Ludwig's angina
- Surgical anatomy and physiology of salivary glands, submandibular sialadenitis, salivary calculi, parotitis, tumors of salivary glands.

DISEASES OF THE LARYNX

- Surgical anatomy and physiology of larynx with reference to phonation and respiration
- Acute infection of larynx
  - Acute laryngitis, laryngotracheobronchitis (LTB), diphtheritic laryngitis, acute epiglottitis
- Stridor
  - Causes of stridor and management
- Hoarseness of voice
  - History-taking, causes and management
- Chronic infections of larynx
  - Chronic nonspecific and specific laryngitis, granulomatous conditions of larynx
- Neurological infections of larynx
  - Cord palsy
    - Diagnosis and management
- Tumors of larynx
  - Diagnosis of laryngeal tumors and management.

DISEASES OF THE TRACHEA

- Surgical anatomy of trachea, stridor, tracheostomy in detail.

DISEASES OF THE ESOPHAGUS

- Surgical anatomy, physiology of deglutition
- Causes of dysphagia, diagnosis and management
- Diseases, such as congenital atresia, injuries (traumatic and chemical)
- Foreign body
- Esophagoscopy
- Neurological problems
- Oncology.

DISEASES OF THE BRONCHUS

- Bronchoscopy
  - Indications, contraindications and complications of foreign body in bronchus.

SECTION III: DISEASES OF ORAL CAVITY AND SALIVARY GLANDS

CHAPTER 42: ANATOMY OF ORAL CAVITY

None

CHAPTER 43: COMMON DISORDERS OF ORAL CAVITY

Short Essays

1. Vincent's angina.	362	J03, D06(OS)
2. Oral submucous fibrosis.	146	J10(RS2), J14(RS3), D00, J02, D04

Short Answer

1. Vincent's angina.	362	D00(OS), D03(OS)

CHAPTER 44: TUMORS OF ORAL CAVITY

Short Essays

1. Premalignant conditions of the oral cavity.	18	D14, J06(OS)
2. Leukoplakia.	18	D12

Short Answers

1. Ranula.	187	J11(RS2), D11(RS2), D16(RS3), J14
2. Premalignant conditions of oral cavity.	18	D07(RS2), J10
3. Leukoplakia (of oral cavity/tongue).	18	D17(RS3), D00, J02, D04, J07

CHAPTER 45: NON-NEOPLASTIC DISORDERS OF SALIVARY GLANDS

Short Essay

1. Management of sialolithiasis.	347	D05

Short Answers

1. Submandibular salivary calculus.	347	D01
2. Treatment of salivary calculi.	347	J17(RS3)

CHAPTER 46: NEOPLASMS OF SALIVARY GLANDS

Short Essay

1. Parotid neoplasms.	293	D14(RS3)

Short Answer

1. Pleomorphic adenoma (clinical features).	274	D13(RS3), D06

SECTION VI: THYROID GLAND AND ITS DISORDERS

CHAPTER 66: THYROID GLAND AND ITS DISORDERS

Short Essay

1. Lingual thyroid.	34	J08(RS2)

Short Answer

1. Lingual thyroid.	34	J12(RS2), J13(RS3)

SECTION VII: DISEASES OF ESOPHAGUS

CHAPTER 67: ANATOMY AND PHYSIOLOGY OF ESOPHAGUS

Long Essay

1. Discuss the physiological basis and mechanism (phases) of deglutition.	44	D08(RS2), J14

Short Essay

1. Describe the mechanism of deglutination.	44	J01(OS)

Short Answer

1. Constrictions of esophagus.	314	D15(RS3)

CHAPTER 68: DISORDERS OF ESOPHAGUS

Short Essays

1. Esophageal perforation.	21	J16(OS)
2. Plummer-Vinson (Paterson Brown Kelly) syndrome.	292	D14(RS3), D05, J07, D13, J07(OS), D09(OS), J10(OS)
3. Globus hystericus.	233	D06
4. Achalasia cardia.	379	J07, D00(OS), D07(OS), J12(OS)

Short Answers

1. Esophageal perforations.	21	D07(RS2)
2. Plummer-Vinson (Patterson Kelly) syndrome.	292	J15(RS3), J08, J03(OS), J16(OS)
3. Globus pharynges (globus hystericus).	233	J12(RS2), J13(RS3), J11
4. Achalasia cardia.	379	D03(OS)

CHAPTER 69: DYSPHAGIA

Long Essay

1. How will you manage a case of 50 years old woman presenting with dysphagia.	173	D15

Short Essays

1. Dysphagia—causes/management.	173	D10(RS2), D17(RS3), J02, J15, J02(OS), D02(OS)
2. Dysphagia lusoria.	174	D11

Short Answer

1. Dysphagia lusoria.	174	J11(OS)

CHAPTER 70: FOREIGN BODIES IN FOOD PASSAGE

Short Essay

1. Clinical features and management of foreign bodies in esophagus.	380	J09

Short Answers

1. Foreign body in cricopharynx.	380	D10

SECTION IV: DISEASES OF PHARYNX

CHAPTER 47: ANATOMY AND PHYSIOLOGY OF PHARYNX

Short Essays

1. Describe in detail the surgical approaches to nasopharynx.	340	J17(RS3)
2. Killian's dehiscence.	279	D11
3. What is Killian's dehiscence? Discuss management of pharyngeal pouch.	279	J14(RS3)
4. Describe the Waldeyer's ring? Explain its importance.	299	J15(RS3), J03, J02(OS), J09(OS)
5. Pyriform fossa.	89	J09(RS2)

Short Answers

1. Killian's dehiscence.	279	D11(RS2), J12(OS)
2. Waldeyer's ring.	299	D09(RS2), J11(RS2), D12(RS3), D13(RS3), D16(RS3), D08, J10, J07(OS)
3. Fossa of Rosenmuller.	296	D14(RS3)
4. Pyriform sinus (fossa).	89	J15(RS3), D15(RS3)

CHAPTER 48: ADENOIDS AND OTHER INFLAMMATIONS OF NASOPHARYNX

Short Essays

1. Etiology, clinical features and management of adenoiditis.	322	J16(RS3), J04
2. Adenoid facies.	323	D11(RS2), D02, D99(OS), J00(OS), D12(OS)

Short Answer

1. Adenoid facies.	323	J12(RS2), J13(RS3), J14(RS3), D10, J14, J17, D02(OS)

CHAPTER 49: TUMORS OF NASOPHARYNX

Long Essays

1. Discuss the etiopathology, clinical features, diagnosis and management of juvenile nasopharyngeal angiofibroma (JNA).	102	D09(RS2), J11(RS2), D16(RS3), J01, D01, D08, D14, D12(OS)
2. Discuss etiopathology, clinical features and management of carcinoma, nasopharynx.	27	J08(RS2)

Short Essays

1. Juvenile nasopharyngeal angiofibroma (JNA)—clinical features, diagnosis, management.	102	D10(RS2), D12(RS3), J15(RS3), J04, D05, J09, D12, J02(OS)
2. Carcinoma nasopharynx—management.	27	J06, D06, D01(OS), J03(OS)

Short Answers

1. Frog face deformity.	103	J12(OS)
2. Trotter's triad in nasopharyngeal carcinoma.	29	J06(OS)

CHAPTER 50: ACUTE AND CHRONIC PHARYNGITIS

Short Essays

1. Describe tonsillar keratosis.	315	D00
2. Write short note on keratosis pharyngitis.	315	J06

Short Answers

1. Hyperkeratosis of tonsil.	315	D10
2. Keratosis pharyngis.	315	D15(RS3)

CHAPTER 51: ACUTE AND CHRONIC TONSILLITIS

Long Essays

1. Discuss the etiopathology, clinical diagnosis and management of acute tonsillitis.	374	J13(OS)
2. Enumerate the conditions causing patch on the tonsils and their management.	207	D02, D04
3. Discuss the types, clinicopathological features and management of chronic tonsillitis.	305	J10, D07(OS)

Short Essays

1. Anatomy of palatine tonsil.	127	D15
2. Acute tonsillitis—clinical features and management.	374	D12
3. Membranous tonsillitis.	143	J10(RS2)
4. Differential diagnosis (causes) of a white patch (membrane) on the tonsil.	207	D11(RS2), J16(RS3), J17(RS3), J04, J06, J07, D10(OS)
5. How would you diagnose and treat tonsillar diphtheria?	376	D10
6. Chronic tonsillitis—clinical features (cardinal signs) and management.	305	D06, D13

Short Answers

1. Anatomy of palatine tonsil.	127	D06
2. Lateral relations of tonsils.	128	D11
3. Blood supply of palatine tonsil.	129	D09(RS2), D11(RS2), D07, J12, D12
4. Mention types of acute tonsillitis.	374	D12(OS)
5. Membranous conditions of tonsil.	208	D07(RS2)
6. Cardinal signs of chronic tonsillitis.	305	J15(RS3), J16(RS3), D05
7. Enumerate complications of chronic tonsillitis.	306	D14
8. Tonsillolith.	352	D17(RS3), J13
9. Lingual tonsillitis.	368	D02, J05

CHAPTER 52: HEAD AND NECK SPACE INFECTIONS

Long Essays

1. Enumerate the ENT conditions presenting with trismus. Discuss the etiopathology, clinical features and management of peritonsillar abscess (Quinsy).	319, 180	D03, J17
2. Discuss the etiopathology, clinical features and management of deep neck space infections.	105	D09(RS2)
3. Describe the anatomy of retropharyngeal space. Discuss the etiopathogenesis, clinical features and management of (acute) retropharyngeal abscess.	105	D14(RS3), J07, J09(OS)
4. Name the two types of retropharyngeal abscess. Describe the etiology, pathogenesis, clinical features and treatment of any one of them.	106	D00

Short Essays

1. Ludwig's angina.	198	D11(RS2), D15(RS3), D17(RS3), J01, J13, D00(OS), D11(OS)
2. Peritonsillar abscess (quinsy)—define, etiopathogenesis, clinical features and management.	180	J11(RS2), J14(RS3), D15(RS3), D16(RS3), J01, D01, J02, J08, D08, D10, J12, J00(OS), J01(OS), J03(OS), D05(OS), J07(OS), J10(OS), D11(OS), J13(OS), J14(OS)
3. Retropharyngeal abscess—etiology and management.	106	J08(RS2), J14(RS3), J09
4. Acute retropharyngeal abscess—etiology, clinical features and management.	107	D13(RS3), D08, D11, J12, D16(OS)
5. Chronic retropharyngeal abscess.	107	J16(RS3), D02
6. Tuberculous cervical lymphadenitis.	363	J07, J14
7. Parapharyngeal space (anatomy and its surgical approaches).	106	J17(RS3), J02(OS), D08(OS)
8. Parapharyngeal space abscess.	108	D14, D15

Short Answers

1. Ludwig's angina.	198	D10(RS2), J16(RS3), J17(RS3), D05, J09, D99(OS)
2. Peritonsillar abscess (quinsy).	180	D07(RS2), J16, D16, D01(OS), J02(OS), D02(OS)
3. Space of Gillette.	106	D01, J02, J05
4. Acute retropharyngeal abscess.	107	D16
5. Parapharyngeal space.	106	D12(RS3), J03
6. Parapharyngeal abscess.	108	J10

CHAPTER 53: TUMORS OF OROPHARYNX

Short Essays

1. Etiology of oropharyngeal cancer.	35	J08(RS2)
2. Eagle's syndrome.	147	J10(RS2), D08, J05(OS)

Short Answers

1. Mention the risk factors of cancer oropharynx.	35	J16(OS)
2. Elongated styloid process (Eagle's syndrome).	147	D14(RS3), J02, D11, J10(OS)

CHAPTER 54: TUMORS OF THE HYPOPHARYNX AND PHARYNGEAL POUCH

Short Essay

1. Post-cricoid malignancy.	33	J08(RS2)

CHAPTER 55: SNORING AND SLEEP APNEA

Short Essay

1. Obstructive sleep apnea syndrome.	144	J10(RS2), D10(RS2), D12(RS3), D14(RS3), J17

Short Answer

1. Sleep apnea.	144	D09(RS2), J13

SECTION V: DISEASES OF LARYNX AND TRACHEA

CHAPTER 56: ANATOMY AND PHYSIOLOGY OF LARYNX

Long Essay

1. Discuss the physiology of phonation.	30	J08(RS2)

Short Essays

1. Intrinsic muscles of larynx.	31	J08(RS2)
2. Differences between adult and infant's larynx.	89	J09(RS2), D11(RS2), D15
3. Functions of larynx.	242	D12(RS3)
4. Describe the mechanism of phonation.	30	D10(OS)

Short Answers

1. Laryngeal cartilages .	96	J09(RS2)
2. Unpaired cartilages of larynx.	96	D11, J06(OS)
3. Tensors of the vocal cords.	32	D06(OS)
4. Differences between adult and infant larynx.	89	D10(RS2)
5. Functions of larynx.	242	I10(RS2), D14

CHAPTER 57: LARYNGOTRACHEAL TRAUMA

Long Essay

1. Discuss the etiopathology, clinical features and management of laryngotracheal trauma.	307	D15(RS3)

CHAPTER 58: ACUTE AND CHRONIC INFLAMMATIONS OF LARYNX

Short Essays

1. Acute epiglotitis (clinical features and management).	35	J08(RS2), D17(RS3), D12
2. Laryngeal diphtheria.	376	D14
3. Tuberculosis of larynx.	377	J15

Short Answers

1. Epiglottitis in children.	35	D00, D04
2. Acute epiglottitis.	35	D01(OS)
3. Management of acute epiglotitis.	36	D14(RS3)
4. Reinke's edema.	150	J10(RS2), J11(RS2), D16(RS3), D14
5. Features of tubercular laryngitis.	377	J09

CHAPTER 59: CONGENITAL LESIONS OF LARYNX AND STRIDOR

Long Essays

1. Define stridor. Enumerate the causes of stridor. How do you manage a patient of stridor?	320	J16(RS3), J03, J11
2. Classify the causes of stridor in a child. Discuss the clinical features and management of juvenile laryngeal papillomatosis.	320, 15	D05

Short Essays

1. Laryngomalacia (congenital laryngeal stridor).	122	D09(RS2), J14, D99(OS)
2. Subglottic stenosis.	369	J17
3. Stridor—define, causes (in children).	320	J14(RS3), D00, D04, J16, D02(OS)

Short Answers

1. Laryngomalacia.	122	D15(RS3), J07, J12, D02(OS), J11(OS)
2. Subglottic stenosis.	369	J01
3. Laryngeal web.	330	J16(RS3), D02, J05, J16
4. Stridor.	320	J12(RS2), J13(RS3), D13(RS3), J13(OS)
5. Etiology of stridor in children.	320	J15(RS3)
6. Enumerate causes of congenital laryngeal stridor.	122	J10

CHAPTER 60: LARYNGEAL PARALYSIS

Short Essays

1. Nerve supply of larynx.	311	D15(RS3)
2. Difference between the right and left recurrent laryngeal nerve anatomy.	130	J05
3. Enumerate the causes of vocal cord paralysis. How do you investigate and manage a case of unilateral vocal cord paralysis.	353	J02, D04
4. Discuss the causes of unilateral vocal cord palsy.	353	D07(OS)
5. Causes of left recurrent laryngeal nerve paralysis.	353	D06
6. What is Dysphagia? Mention the causes of left recurrent laryngeal palsy.	173, 353	J14(OS)

Short Answers

1. Causes of left vocal cord paralysis.	353	J17
2. Recurrent laryngeal nerve.	129	D09(RS2)
3. Bilateral adductor paralysis.	151	J10(RS2)

CHAPTER 61: BENIGN TUMORS OF LARYNX

Long Essay

1. Discuss the etiopathology, clinical features, management and complications of juvenile laryngeal papilloma.	15	J15(RS3)

Short Essays

1. Singer's nodule (vocal nodule).	325	J16(RS3), J04, J07, D08, D10, D13, J03(OS), J05(OS), D06(OS), D09(OS)
2. Vocal polyp (etiopathology and management).	43	J06, D03(OS)
3. Give an account of laryngocele.	350	D01, J05, J07, J12
4. Papillomas of larynx.	14	D07(RS2)
5. Juvenile laryngeal papillomatosis.	15	D17(RS3), D13
6. Discuss in brief multiple papillomas of larynx.	14	J08, J12(OS)
7. Recurrent laryngeal papilloma.	15	D03(OS)

Short Answers

1. Premalignant lesions of larynx.	286	J14(RS3)
2. Vocal nodule (Singer's nodule/laryngeal nodules)—management.	325	J14(RS3), D14(RS3), D17(RS3), J01, D01, D03, J08, D12, J13, D15, J17, J00(OS), J02(OS), J11(OS)
3. Vocal cord polyps.	43	J08(RS2), J11(RS2), D12(RS3), D16(RS3), J10
4. Laryngocele.	350	D17(RS3)
5. Laryngeal papilloma.	14	J15(RS3)

CHAPTER 62: CANCER LARYNX

Long Essays

1. Describe the etiology, symptoms, signs, investigations and treatment of carcinoma larynx.	158	D10(RS2)
2. How do you manage a stage III carcinoma larynx?	163	D07(RS2)

Short Essays

1. Pharyngocutaneous fistula.	38	J08(RS2)
2. Glottic cancers have high cure rate. Give reasons.	366	D00, J03, D04
3. TNM classification of carcinoma of glottis.	162	J15
4. Carcinoma of the vocal cord.	159	D99(OS)
5. Mention signs and symptoms of carcinoma glottis. How do you do staging of the same?	160	J13(OS)
6. Investigations and treatment of glottic cancer.	161	J04
7. Treatment of carcinoma larynx (T1 lesion).	163	J00(OS)
8. Speech rehabilitation following laryngectomy.	378	D05

Short Answers

1. TNM classification of carcinoma larynx.	162	D07
2. T1 glottic malignancy.	162	D03
3. Esophageal voice.	378	D00, D02, D04, J05

CHAPTER 63: VOICE AND SPEECH DISORDERS

Short Essays

1. Discuss the management of an adult patient presenting with hoarseness of voice.	8	J17(RS3)
2. 'Hoarse voice'—causes (in 50 years old male).	7	D07(RS2), D13
3. Functional aphonia.	151	D05, D11
4. Puberphonia.	134	D07(OS)
5. Rhinolalia.	72	J10

Short Answers

1. Enumerate causes of hoarseness in 50 years old female.	7	J10
2. Sudden aphonia.	151	D05(OS)
3. Puberphonia.	134	D09(RS2), J11, J15, D99(OS), J02(OS), D03(OS)
4. Rhinolalia.	72	D08(RS2)
5. Rhinolalia aperta (causes).	72	D01, J02, J13(OS)
6. Rhinolalia clausa.	72	J03, J16, J05(OS)

CHAPTER 64: TRACHEOSTOMY AND OTHER PROCEDURES FOR AIRWAY MANAGEMENT

Long Essay

1. Tracheostomy—define, indications, surgical procedure, postoperative care and complications.	9	J05(OS), D06(OS), J07(OS), J16(OS)

Short Essays

1. Advantages of tracheostomy over endotracheal intubation.	12	D06
2. Tracheostomy—types, indications (nonobstructive), procedure and complications.	9	D07(RS2), D08(RS2), J11(RS2), D12(RS3), J15(RS3), D16(RS3), J17(RS3), J04, D04, J08, J10, D14, J17, D00(OS), D07(OS), D12(OS)
3. Postoperative management after tracheostomy.	11	J03(OS)
4. What is emergency tracheostomy? Name the indications for it.	9	D02

Short Answers

1. Indications for tracheostomy.	9	D10(RS2), J12
2. Nonobstructive indication for tracheostomy.	9	D15
3. Decannulation of tracheostomy.	12	D11
4. Causes of decanulation problem.	12	D03
5. Complications of tracheostomy.	12	D05, J08, J16
6. Cricothyrotomy.	369	D01(OS)

CHAPTER 65: FOREIGN BODIES IN AIR PASSAGE

Short Essay

1. Foreign body in bronchus.	184	J11(RS2), D16(RS3), J13, D16

SECTION III: DISEASES OF ORAL CAVITY AND SALIVARY GLANDS

CHAPTER 42: ANATOMY OF ORAL CAVITY

None

CHAPTER 43: COMMON DISORDERS OF ORAL CAVITY

Short Essays

1. Vincent's angina.	362	J03, D06(OS)
2. Oral submucous fibrosis.	146	J10(RS2), J14(RS3), D00, J02, D04

Short Answer

1. Vincent's angina.	362	D00(OS), D03(OS)

CHAPTER 44: TUMORS OF ORAL CAVITY

Short Essays

1. Premalignant conditions of the oral cavity.	18	D14, J06(OS)
2. Leukoplakia.	18	D12

Short Answers

1. Ranula.	187	J11(RS2), D11(RS2), D16(RS3), J14
2. Premalignant conditions of oral cavity.	18	D07(RS2), J10
3. Leukoplakia (of oral cavity/tongue).	18	D17(RS3), D00, J02, D04, J07

CHAPTER 45: NON-NEOPLASTIC DISORDERS OF SALIVARY GLANDS

Short Essay

1. Management of sialolithiasis.	347	D05

Short Answers

1. Submandibular salivary calculus.	347	D01
2. Treatment of salivary calculi.	347	J17(RS3)

CHAPTER 46: NEOPLASMS OF SALIVARY GLANDS

Short Essay

1. Parotid neoplasms.	293	D14(RS3)

Short Answer

1. Pleomorphic adenoma (clinical features).	274	D13(RS3), D06

11. Oral submucous fibrosis.

- Oral submucous fibrosis is a collagen disorder affecting oral cavity and occasionally pharynx
- Also called idiopathic oral fibrosis.

Etiology

Risk factors (TAANI – Anushka Sharma's name in Rab ne mila di Jodi)	*Predisposing factors*
• Tobacco chewing—major risk factor • Areca nut chewing—causative agent if chewed alone, with tobacco or in form of pan • Alcohol—increases risk by 2 fold • Nutritional deficiency—deficiency of vitamins and micronutrients due to lesser intake of fruits and vegetables • Immune response—due to cell-mediated immune reaction to arecoline in areca nuts	• Low socioeconomic condition • Multifactorial (synergistic effect of numerous factors like tobacco chewing, alcohol)

Pathogenesis

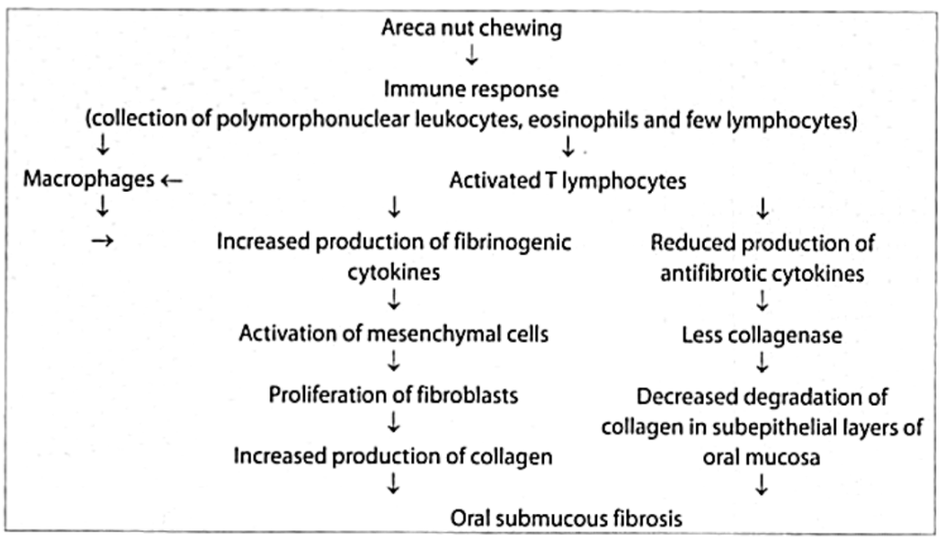

Pathology

Initial stage	*Later stage*
• Presence of polymorphonuclear leukocytes, eosinophils and few lymphocytes • Fibroblastic transformation of connective tissue in lamina propria associated with epithelial atrophy	• Presence of lymphocytes and plasma cells • Marked fibrosis

Clinical Features

- Mostly affects females aged 20–50 years.

Stages	*Symptoms*	*Signs*
Prodromal	• Difficulty in chewing • Intolerance to chilies and spicy food	• Patchy redness of mucosa over soft palate, faucial pillars and buccal mucosa with formation of vesicles which may burst forming superficial ulcers
Initial	• Soreness of mouth with constant burning sensation, worsening during meals (pungent spicy food)	• Blanching of mucosa with loss suppleness • Vertical and circular palpable fibrotic bands in affected area resulting in marble-like appearance of mucosa
	• Recurrent ulcers in mouth (on palate and pillars)	• Restrictive mobility of soft palate, tongue and jaw due to fibrosis and scarring of underlying muscles • Obliteration of vestibule of mouth and inability to puff out cheeks • Small contracted uvula • Stiff and small tongue • Progressive trismus (incisor bite reduced to 2.5 cm from normal 4.5 cm) • Poor orodental hygiene with carious teeth
Advanced	• Difficulty to open mouth fully • Difficulty to protrude tongue	• Leukoplakia • Speech and hearing deficit (because of involvement of tongue and Eustachian tube)

Investigations

a. Blood picture	• Anemia
b. ESR	• Raised
c. Biopsy	• Atrophy of epithelial layers with increased mitotic activity in basal layer • Increased thickening and hyalinized collagen and fibrotic tissue in subepithelial tissue • Infiltration by inflammatory cells

Differential Diagnosis

Leukoplakia	*Lichen planus*	*Thrush*
• Thickened mucosa with cracks on patches • Usually affects cheeks, lip and tongue	• Thin white submucosal bands • Also affects skin	• Fungal infection with curd-like plaques

Treatment

Supportive	*Specific*	
	Conservative	*Operative*
• Avoid irritants like areca nuts, pan, tobacco, spicy foods • Vitamin A, zinc and antioxidants to treat nutritional deficiency • Dental hygiene • Jaw opening exercises	• Steroids – Injection of 1 mL dexamethasone (4 mg) along with 1500 IU hylase into affected area on either side twice weekly for 8–10 weeks	*Indications* • To relieve trismus in advanced cases *Techniques* • Simple release of fibrosis and skin grafting • Bilateral tongue flap • Nasolabial flap • Island palatal mucoperiosteal flap • Bilateral radial forearm free flap • Surgical excision and buccal fat pad graft • Superficial temporal fascia flap and split skin graft • Coronoidectomy and temporal muscle myotomy

Complications

- Malignant transformation (3–8%).

13. Premalignant conditions of oral cavity.

- Premalignant conditions are lesion which have potential to turn malignant if not managed promptly

Premalignant Conditions of Oral Cavity and Pharynx

a. Leukoplakia
   - Leukoplakia is a clinical white patch in oral cavity that cannot characterized clinically or pathologically as any other disease (WHO).

Etiology	Sites involved	Pathology (microscopic appearance)
• Smoking • Tobacco chewing • Alcohol abuse (particularly if combined with alcohol abuse) • Chronic trauma from ill fitting dentures or cheek bites • Spicy food • Syphilis • Submucous fibrosis • Hyperplastic candidiasis • Plummer Vinson syndrome	• Buccal mucosa (most common) • Oral commissures • Floor of mouth • Tongue • Gingivobuccal sulcus • Mucosal surface of lip	• Mild to severe epithelial dysplasia • Degree of dysplasia related to malignant potential • Hyperkeratosis and parakeratosis with widening of rete pegs

Clinical features

- Mostly seen in 4th decade of life
- Males affected 2–3 times more compared to females.

Symptoms	Signs
• White keratotic plaque in mouth which cannot be rubbed off	• Smooth or wrinkled white patch (homogenous type) • White patches or nodules on erythematous base (nodular or speckled type) • Leukoplakia (white patch) interspersed with erythroplakia along with erosions and fissures (Erosive type or erythroleukoplakia)

Investigations

- Biopsy to rule out malignacy.

Treatment

Supportive	Specific
• Spontaneous regression if causative agent is removed	• Surgical excision or ablation with laser or cryotherapy for suspicious small lesions

Differential diagnosis	Prognosis (malignant potential)
• Lichen planus • Discoid lupus erythematosus • White spongy nevus • Candidiasis	• Average 5% of leukoplakia (1–17.5%) turn malignant • Malignant potential depends upon site and type of leukoplakia and duration of follow up • Nodular and erosive types are more associated with malignancy

b. Erythroplakia
- Erythroplakia is red patch or plaque on oral mucosal surface
- Red color is due to decreased keratinization and resulting in shining through of underlying red vascular connective tissue of submucosa.

Sites involved	Pathology (microscopic appearance)	Types
• Lower alveolar mucosa • Gingivobuccal sulcus • Floor of mouth	• Erythroplakia exhibits severe dysplasia, carcinoma in situ or frank invasive carcinoma	• Homogenous type • Speckled or granular type • Erythroplakia interspersed with area of leukoplakia

Treatment	Prognosis (malignant potential)
• Excision biopsy • Follow up	• Malignant potential of erythroplakia is 17 times higher than leukoplakia

c. Melanosis and mucosal hyperpigmentation
- Benign pigmented lesions of oral mucosa may transform into malignant melanoma
- Lesion may resemble benign lesions
- Diagnosed by biopsy.

d. Submucous fibrosis
- Tropical disease occurring mainly in Indian subcontinent (India, Pakistan and Bangladesh).

Etiology	Predisposing factors
• Chronic irritation of oral mucosa by betel nuts, spicy foods	i. Irritants – Chewing of paan, tobacco, betel nuts – Rubbing of misri on gums and teeth – Chilies and spicy food ii. Trauma – Repeated mechanical and thermal trauma iii. Nutrition – Poor nourishment may contribute – Associated with vitamin deficiencies iv. Poor dental hygiene

Pathology

Gross appearance	Microscopic appearance
• Diffuse, dense white patch behind last molars and in front of ramus of mandible	• Deposition of fibrous and hyaline tissue in submucosa of oral cavity or oropharynx

Clinical features
- Usually affects between 15–40 years of age
- Females are more likely to be affected.

Symptoms	Signs
• Difficulty in chewing • Burning sensation in oral cavity • Recurrent ulcers of oral cavity • Difficulty in blowing, whistling or sucking due to involvement of cheek • Swelling in neck due to enlargement of lymph nodes	• Diffuse and dense white patches in oral cavity on cheeks, retromolar area, hard and soft palate and oropharynx • Small and contracted uvula • Trismus of mild to severe degree • Vesicle formation leading to painful ulceration in early stages • Lymphadenitis in submandibular region

Investigations	Differential diagnosis
i. Hemogram – May reveal anemia ii. Gastric analysis – May reveal achlorhydria or hyperacidity iii. Biopsy – If malignant change is suspected	i. Trismus ii. Leukoplakia – Thickened mucosa with cracks on patches affecting cheeks, lips and tongue iii. Lichen planus – Thin white submucous fibrous bands which disappear and reappear – Also involves skin iv. Trush – Candidial infection of oral cavity manifesting as curd like plagues

Treatment

Supportive	Specific	
	Conservative	Operative
• Removal of irritants (avoiding pan, tobacco, betel nut chewing) • Physiotherapy for trismus • Antacids for hyperacidity • Antioxidants to prevent dysplastic change • Correction of dental hygiene • Improvement in nutrition	i. Hydrocortisone – 0.5 cc injection of hydrocortisone submucosally on either side once a week for a month – May reduce trismus ii. Hyaluronidase – Injected submucosally to reduced trismus	i. Excision and grafting – Divide fibrous bands in retromolar area and forcibly open mouth – Graft raw area by split skin grafts or rotating lingual mucosal flap ii. Laser surgery (KTP-532 or CO_2) – Useful dividing fibrous bands iii. Condylectomy – In advanced cases with severe trismus

e. Lichen planus
- Premalignant potential in dispute
- Common lesion of oral cavity which can undergo occasional epithelial dysplasia or carcinoma
- Lesion resembles white lace like pattern on oral mucosa
- Biopsy mandatory for diagnosis and assess prognosis.

21. Treatment of salivary calculi.

- Salivary calculi (also termed as sialolithiasis) is formation of stone in salivary gland or their ducts

Etiology	*Common sites*	*Composition*
• Deposition of calcium phosphate on organic matrix of mucin or cellular debris	• Submandibular gland or its duct (Wharton's duct) (because of tortuous course and secretion rich in mucoid and calcium) (90%) • Parotid gland or its duct (10%)	• Organic matrix with inorganic crystalline body carbohydrate and phosphates of calcium and magnesium

Clinical features

Symptoms	*Signs*	*Investigations*
• Painful intermittent swelling of gland before/during meals • Salivary colic due to obstruction of outflow of saliva	• Tenderness over affected gland • Little/no saliva pours out from orifice of Wharton's duct on affected side • Detection of stone on bidigital palpation or visible at opening of duct	• Radiography • X-rays detects radioopaque stones in gland or duct • Sialography or CT scan for radiolucent stones

Treatment

Operative

a. Removal of stone in duct intraorally under local or general anesthesia
   - Grasp tissue immediately behind stone with tenaculum forceps to steady and elevate stone
   - Incise long axis of duct letting stone to slip out
   - Leave wound unsutured.

b. Sialadectomy
   - Removal of gland in case of stone in gland, recurrent stones or unpalpable stones.

10. Parotid neoplasms.

- 80% of salivary neoplasma are parotid neoplasms, 80% are benign and 80% are pleomorphic (Parotid—80%).

Classification

Benign		*Malignant*	
Epithelial	*Mesenchymal*	*Epithelial*	*Mesenchymal*
• Pleomorphic adenoma • Warthin's lymphoma • Oxyphil adenoma	• Hemangioma • Lymphangioma • Lipoma • Neurofibroma	• Mucoepidemoid carcinoma • Adenoid cystic carcinoma • Acinic cell carcinoma • Malignant mixed tumor • Squamous cell carcinoma	• Lymphoma • Sarcoma

Etiology

a. Radiation
- Exposure to ionizing radiation increases risk of both benign and malignant tumors (especially mucoepidermoid carcinoma)

b. Viral
- Epstein-Barr virus is associated with lymphoepithelial carcinoma

c. Smoking
- Warthin's tumor is associated with cigarette smoking

d. Occupational factors
- Increased risk is seen with exposure to silica dust, nickel alloys and nitrosamines (rubber workers) and use of kerosene as cooking fuel

e. Hormonal factors
- High risk in women with a history of early menarche and nulliparity

f. Dietary factors
- Two fold risk seen on consumption of vegetables preserved in salt

g. Genetic factors

i. Allelic loss
- Loss at 12 q in pleomorphic adenomas and multiple losses at 9p, 3p and 17p in carcinoma ex-pleomorphic adenoma
- Loss of heterozygosity occurs at 8q, 12q and 17p in carcinoma expleomorphic adenoma (17p in high disease stage and increased proliferative rate)

ii. Monosomy and polysomy
- Monosomy of chromosome 17 and polysomy of chromosomes 3 and 17 is higher in adenoid cystic carcinoma

iii. Structural rearrangement
- Cytogenetically, monoclonal and high frequency of tumor-specific chromosome bands abnormalities 3p21, 8q12 and 12q14-15 are seen in pleomorphic adenomas
- Ectopic expression of the PLAG1 gene occurs in pleomorphic adenomas with 8q12 aberrations

Features	*Treatment*
Benign tumors	
a. Pleomorphic adenoma – Usually seen in 3rd or 4th decade of life and More likely in females – Painless, firm, smooth, non-tender, lobulated, mobile slow growing mass in lower part of parotid region – Foreign body feeling in throat, dysphagia (if arises from deep lobe) – Skin not adhered to underlying mass – Swelling in lateral pharyngeal wall (parapharyngeal mass) in orophyarnx with tonsil being pushed medially (if arise from deep lobe) – Sudden increase in size, pain, signs of facial paralysis and fixation to neighbouring structures (indication of malignant transformation)	• Superficial parotidectomy with preservation (surgery of choice) • Extracapsular excision (very small superficial tumors) • Total parotidectomy with or without block dissection of neck (malignant transformation)
b. Warthin's lymphoma (Adenolymphoma) – Commonly seen in 5th to 7th decade of life with 5 times male preponderance, involving tail of parotid unilaterally or bilaterally (10%) – Presents as multiple, rounded encapsulated tumours, at time cystic with mucoid or brownish fluid – Epithelial and lymphoid elements are seen on microscopic examination	• Enucleation through superficial parotidectomy
c. Oxyphil adenoma (Oncocytoma) – Rare tumours arising from acidophilic cells called oncocytes, seen mostly in elderly – Involve superficial lobe of parotid and usually do not grow larger than 5cm – Benign oncocytomas are cystic whereas malignant are solid	• Superficial parotidectomy
d. Haemangiomas – Most common benign tumours of parotid in children, predominantly affecting females – Most are discovered at birth, growing rapidly in neonatal period to involute spontaneously – Soft and painless swelling which increase in size with crying or straining – Overlying skin shows bluish discoloration	• Surgical excision if they do not regress spontaneously
e. Lymphangioma – Less common tumours involving submandibular gland along with parotids – Feel soft and cystic	• Surgical excision if they do not regress spontaneously

Malignant tumors

a. Mucoepidermoid carcinoma

- Slow growing tumor that is known to invade facial nerve
- Shows areas of mucin-producing cells and squamous cells on microscopy (hence the name)
- Higher proportion of epidermoid element, more malignant is tumor
- Low grade
  - Good prognosis
  - More common in children
- High grade
  - More aggressive and poor prognosis

- Low grade
  - Treated by superficial or total parotidectomy, preserving facial nerve
- High grade
  - Treated by total parotidectomy, sacrificing facial nerve (if invaded)

b. Adenoid cystic carcinoma (Cylindroma)

- Slow-growing tumor but infiltrates widely into tissue planes, muscles, perineural spaces and lymphatics and thus causes pain and VIIth nerve paralysis
- Local recurrences after surgical excision is common
- Locally metastasize to lymph nodes and distant to lung, brain and bone

- Radical parotidectomy followed by postoperative radiation (if margins are not free of tumor)
- Radical neck dissection if nodal metastases is present

c. Acinic cell carcinoma

- Low-grade tumor
- Presents as a small, firm, movable and encapsulated tumor, sometimes bilateral
- Metastases are rare

- Superficial or total parotidectomy

Features	*Treatment*
d. Malignant mixed tumor – Appears in two varieties, i.e. (i) develops in pre-existing benign mixed tumour or (ii) develops "de novo" – Rapid growth and pain in a benign tumor should always arouse a suspicion of malignant change	• Radical parotidectomy
e. Squamous cell carcinoma – Rapidly growing tumor that infiltrates, causes pain and ulcerates through skin – Can metastasize to neck nodes	• Radical parotidectomy followed by postoperative radiation • Radical neck dissection if nodal metastases is present

Staging (American Joint Committee on Cancer (AJCC) Cancer Staging and UICC TNM classification of malignant tumors of major salivary glands)

Tumor		*Node involvement*		*Metastases*	
Tx	Primary tumor cannot be assessed	Nx	Regional lymph nodes cannot be assessed	Mx	Distant metastasis cannot be assessed
T0	No evidence of primary tumor	N0	No regional lymph node metastasis	M0	No distant metastasis
T1	Tumor ≤ 2 cm size	N1	Single ipsilateral lymph node ≤ 3 cm	M1	Distant metastasis
T2	Tumor 2–4 cm	N2a	Single ipsilateral lymph node 3–6 cm		
T3	Tumor > 4 cm or extraparenchymal extension	N2b	Multiple ipsilateral lymph nodes < 6 cm		
T4a	Tumor invades skin, mandible, ear canal, or facial nerve	N2c	Bilateral or contralateral lymph nodes < 6 cm		
T4b	Tumor invades skull base, pterygoid plates, or encases carotid artery	N3	Metastasis in lymph node > 6 cm		

Grading

Stage I	T1 N0 M0
Stage II	T2 N0 M0
Stage III	T3 N0 M0; T1-3 N1 M0
Stage IVA	T4a N0-1 M0; T1-4a N2 M0
Stage IVB	T4b N0-3 M0; T1-4b N3 M0
Stage IVC	T1-4b N0-3 M1

22. Pleomorphic adenoma.

- Pleomorphic adenoma is most common benign tumor of parotid salivary gland
- Also called mixed tumor.

Etiology

- Age: Usually seen in 3rd or 4th decade of life
- Sex: More likely in females.

Pathology

Gross appearance	*Microscopic appearance*
• Circumscribed, pseudoencapsulated, rounded, at times multilobulated, firm mass, 2–5 cm in diameter with bosselated surface • Cut surface is gray white and bluish, variegated, semitranslucent, usually solid but occasionally may show small cystic space • Consistency is soft and mucoid	• Characterized by pleomorphic or mixed appearance, i.e. epithelial elements present in matrix of mucoid, myxoid and chondroid tissue with predominance of either i. Epithelial component – Consists of cells of ductal or myoepithelial origin arranged in various patterns like ducts, acini, tubules, sheets and strands – Ductal cells are cuboidal or columnar and underlying myoepithelial cells may be polygonal or spindle-shaped resembling smooth muscle cells – Lumen of duct—like structures contain PAS positive epithelial mucin – Focal areas of squamous metaplasia and keratinisation ii. Mesenchymal elements – Consists of loose connective tissue and myxoid, mucoid and chondroid matrix simulating cartilage (pseudocartilage) – Matrix of tumor is a product of myoepithelial cells – Small proportion of cases shows true cartilage and even bone

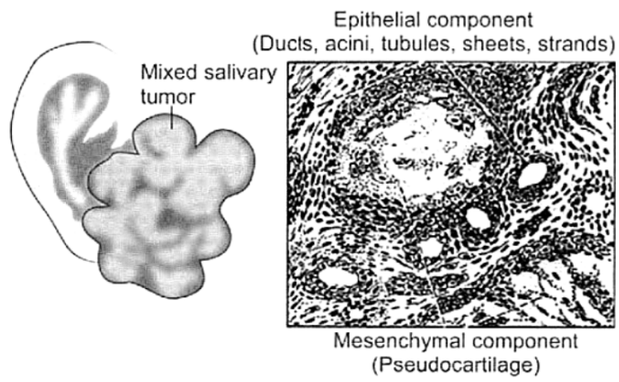

Figure 25: Mixed parotid tumor—pathology

Clinical Features

Symptoms	*Signs*
• Painless swelling in parotid region • Foreign body feeling in throat, dysphagia (if arises from deep lobe)	• Firm, smooth, non-tender, lobulated, mobile slow growing mass in lower part of parotid region • Skin not adhered to underlying mass • Swelling in lateral pharyngeal wall (parapharyngeal mass) in orophyarnx with tonsil being pushed medially (if arise from deep lobe) • Sudden increase in size, pain, signs of facial paralysis and fixation to neighboring structures (indication of malignant transformation)

Investigations

- FNAC
- Sialogram
- CT/MRI.

Treatment

Operative (treatment of choice)

	Extracapsular excision	*Superficial parotidectomy with preservation (surgery of choice)*	*Total parotidectomy with or without block dissection of neck*
Indications	• Very small superficial tumors	• Tumor has broken confines • Recurrent tumor after local excision	• Malignant transformation
Disadvantages	• High recurrence		

15. Ranula.

- Ranula is a mucus retention cyst in the floor of the mouth.

Etiology

- Obstruction of ducts of sublingual salivary glands.

Clinical Features

Symptoms	Signs
• Swelling in the floor of the mouth • Difficulty in chewing and swallowing	• Bluish, translucent cyst in the floor of the mouth on one side of tongue • Fluctuant • Pushes tongue up • Resembles belly of a frog (Lt. rana = frog)

Treatment

Operative

a. Excision
   - For small cysts confined to mouth.

b. Marsupialization
   - For large cysts and plunging ranula.

Complications

Plunging Ranula

- Enlarged cyst present in neck after penetration of mylohyoid muscle
- It is intraoral ranula with cervical extension and is cross fluctuant across mylohyoid.

Pathogenesis

- Usually arises from both submandibular and sublingual salivary glands as mucus retention cyst initially, which reaches neck by passing across mylohyoid muscle.

Features

- Presents as soft, fluctuant, nontender, dumbbell shaped swellings in submandibular region
- It is bidigitally palpable.

Investigations

- Ultrasound and MRI are diagnostic.

Treatment

- Surgical excision through neck approach along excision of submandibular and sublingual salivary glands.

SECTION IV: DISEASES OF PHARYNX

CHAPTER 47: ANATOMY AND PHYSIOLOGY OF PHARYNX

Short Essays

1. Describe in detail the surgical approaches to nasopharynx.	340	J17(RS3)
2. Killian's dehiscence.	279	D11
3. What is Killian's dehiscence? Discuss management of pharyngeal pouch.	279	J14(RS3)
4. Describe the Waldeyer's ring? Explain its importance.	299	J15(RS3), J03, J02(OS), J09(OS)
5. Pyriform fossa.	89	J09(RS2)

Short Answers

1. Killian's dehiscence.	279	D11(RS2), J12(OS)
2. Waldeyer's ring.	299	D09(RS2), J11(RS2), D12(RS3), D13(RS3), D16(RS3), D08, J10, J07(OS)
3. Fossa of Rosenmuller.	296	D14(RS3)
4. Pyriform sinus (fossa).	89	J15(RS3), D15(RS3)

CHAPTER 48: ADENOIDS AND OTHER INFLAMMATIONS OF NASOPHARYNX

Short Essays

1. Etiology, clinical features and management of adenoiditis.	322	J16(RS3), J04
2. Adenoid facies.	323	D11(RS2), D02, D99(OS), J00(OS), D12(OS)

Short Answer

1. Adenoid facies.	323	J12(RS2), J13(RS3), J14(RS3), D10, J14, J17, D02(OS)

CHAPTER 49: TUMORS OF NASOPHARYNX

Long Essays

1. Discuss the etiopathology, clinical features, diagnosis and management of juvenile nasopharyngeal angiofibroma (JNA).	102	D09(RS2), J11(RS2), D16(RS3), J01, D01, D08, D14, D12(OS)
2. Discuss etiopathology, clinical features and management of carcinoma, nasopharynx.	27	J08(RS2)

Short Essays

1. Juvenile nasopharyngeal angiofibroma (JNA)—clinical features, diagnosis, management.	102	D10(RS2), D12(RS3), J15(RS3), J04, D05, J09, D12, J02(OS)
2. Carcinoma nasopharynx—management.	27	J06, D06, D01(OS), J03(OS)

Short Answers

1. Frog face deformity.	103	J12(OS)
2. Trotter's triad in nasopharyngeal carcinoma.	29	J06(OS)

CHAPTER 50: ACUTE AND CHRONIC PHARYNGITIS

Short Essays

1. Describe tonsillar keratosis.	315	D00
2. Write short note on keratosis pharyngitis.	315	J06

Short Answers

1. Hyperkeratosis of tonsil.	315	D10
2. Keratosis pharyngis.	315	D15(RS3)

10. What is Killian's dehiscence? Discuss management of pharyngeal pouch.

Killian's Dehiscence

- Killian's dehiscence is a potential space in posterior pharyngeal wall
- Also called gateway of tears (because perforation may occur during esophagoscopy).

Boundaries

Superior	*Inferior*
• Thyropharyngeus (oblique fibers of inferior constrictor)	• Cricopharyngeus (transverse fibers of inferior constrictor)

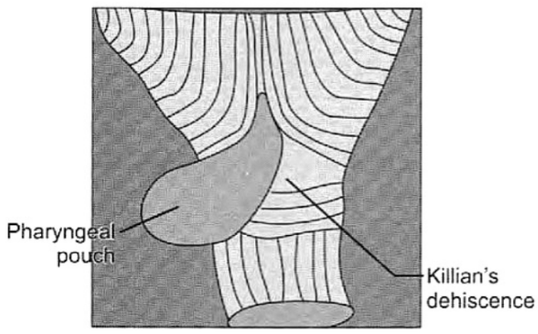

Figure 1: Killian's dehiscence

Applied Anatomy

- Embryologically weak site resulting in herniation of pharyngeal mucosa through it in cases of pharyngeal pouch
- Pharyngeal pouch is more likely to occur when food exerts pressure over this area due to neuromuscular incoordination between propulsive thyropharygeus (supplied by pharyngeal plexus) and sphincteric cricopharyngeus (supplied by recurrent laryngeal nerve)
- Pharygneal pouch, thus, formed cannot expand posteriorly due to vertebral column, therefore grows downwards pressing over esophagus resulting in dysphagia.

Pharyngeal Pouch

- Pharyngeal pouch is a pulsion hypopharyngeal diverticulum where hypopharyngeal mucosa herniates through Killian's dehiscence, a weak area between two parts (thyropharyngeal and cricopharyngeal) of inferior constrictor muscle
- Also called as hypopharyngeal diverticulum, Zenker's diverticulum or upper esophageal diverticulae.

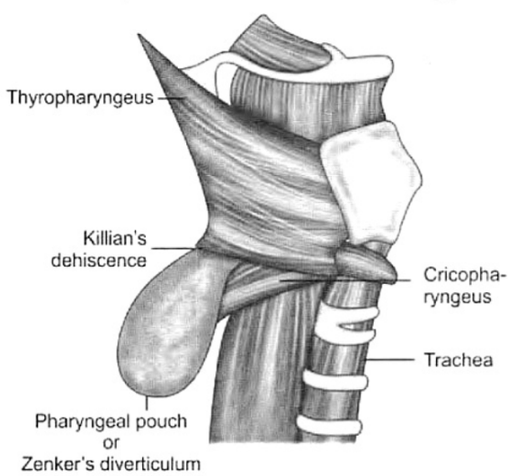

Figure 2: Pharyngeal pouch

Etiopathogenesis

Etiology	*Pathology*
• Unknown; may be due to spasm of cricopharyngeal sphincter or its incoordinated contractions during deglutition	• Herniation of pouch starts in midline, at first behind esophagus and, then, comes to lie on its left • Mouth of sac is wider than pening of esophagus and, thus, food preferentially enters the sac

6. Describe in detail the surgical approaches to nasopharynx.

Surgical difficult to assess nasopharynx	*Ideal surgical approach*	*Criteria to choose surgical approach*
• Central location • Surrounding facial skeleton, skull base • Presence of great vessels and lower cranial nerves	• Provide adequate exposure to nasopharynx for tumor resection • Great vessels must be safely controlled • Lower cranial nerves should be spared - a difficult task indeed	• Extent of tumor • Surgical expertise • Facilities available

Surgical Approaches

Anterior approaches	
a. Lateral rhinotomy	• Well exposes nasal cavity and choana • Can be used alone or in combination with other approaches to enhance nasopharynx exposure Application • Useful in resection of anteriorly placed tumors
b. Transnasal transmaxillary approach	• Combination of lateral rhinotomy with medial/subtotal maxillectomy • Exposes nasopharynx, ipsilateral sphenoethmoidal complex, pterygopalatine fossa and medial en of infratemporal fossa
c. Midfacial degloving approach	• Bilateral transnasal, transmaxillary approach performed via sublabial incision • Exposes pterygopalatine fossa and medial end of infratemporal fossa Advantages • Avoids facial scar • Safeguards infraorbital nerves on both sides
d. Lefort I osteotomy	• Transverse maxillary osteotomy through both maxillary sinuses through a sublabial incision allowing whole hard palate and both inferior maxillae to be down fractured • Exposes central skull base and nasopharynx Advantages • No facial scars
e. Maxillary swing approach	• Most common approach • Exposes nasopharynx and surrounding areas from anterolateral aspect • Through Weber Ferguson incision, maxilla is separated from its bony attachments and swung laterally intact with masseter muscle and cheek flap • Access to opposite side can be established by removing the posterior portion of nasal septum • After tumor resection, maxilla is swung back and fixed to facial skeleton
Inferior approaches	
a. Transpalatal approach	• Nasopharynx is accessed by raising palatal mucoperiosteal flap off the hard palate, separating soft palate from its bony portion and removing posterior edge of bony hard palate as needed • Greater palatine neurovascular bundle are mobilized bilaterally to prevent flap necrosis
b. Mandibular swing approach	• Combination of transcervical, transmandibular, transpalatal approach via Frazier incision • Soft tissues including parotid gland are elevated from mandible • Midportion of ascending ramus of mandible including the coronoid process is cut and removed to facilitate exposure and to prevent postoperative trismus • Lateral and medial pterygoid muscles are divided to enter the nasopharynx • Tracheostomy is a must to secure the airway • Dead space after tumor removal needs to be repaired
Lateral approach	
a. Infratemproal fossa approach	• Approach is via infratemporal fossa Disadvantages • Limited by facial nerve and carotid sheath Application • Used when tumor extends laterally to involve parapharyngeal space

6. Pyriform fossa.

- Pyriform fossa is a mucus covered, pear shaped deep depression on lateral wall of laryngopharynx on each side of laryngeal inlet.
- Also called pyriform sinus.

Extent

- From pharygoepiglottic fold to upper end of esophagus.

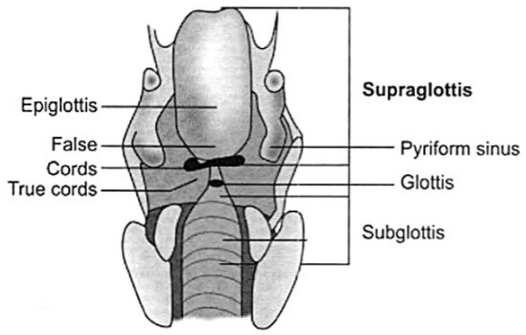

Figure 11: Pyriform fossa

Boundaries

Medially	*Laterally*	*Superiorly*
• Aryepiglottic fold • Posterolateral surfaces of arytenoid and cricoid cartilages	• Mucous membrane covering medial surface of lamina of thyroid cartilage • Thyrohyoid membrane	• Pharyngoepiglottic fold

Applied Anatomy

- Pyriform fossa forms lateral channel for food
- It acts as a catch point for foreign body
- Internal branch of superior laryngeal nerve running submucosally in lateral wall of sinus is accessible for loc anesthesia and may also refer pain of carcinoma in pyriform fossa to ear
- Sometimes it is artificially deepened to smuggle materials.

15. Fossa of Rosenmuller.

- Also called pharyngeal recess.

Location

- At base of skull, behind ostium of Eustachian tube.

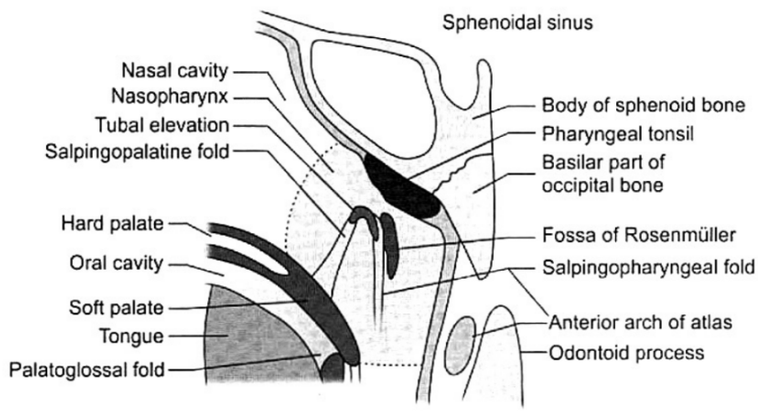

Figure 3: Fossa of Rosenmuller

Boundaries

• Anteriorly	Eustachian tube Levator palati muscle
• Posteriorly	Posterior pharyngeal wall mucosa overlying pharyngobasilar fascia
• Superiorly	Base of skull till foramen lacerum and floor of carotid canal
• Posterolateral (apex)	Carotid canal opening Petrous bone apex (posteriorly) Foramen ovale and spinosum (laterally)
• Laterally	Tensor palatini muscle Mandibular nerve (in prestyloid compartment)
• Medially	Nasopharyngeal cavity

Contents

- Retropharyngeal lymph node (Node of Rouviere).

Clinical Significance

- Common site for nasopharyngeal carcinoma.

3. Waldeyer's rings.

- Waldeyer's ring is a subepithelial collection of lymphoid tissue scattered in circular fashion in nasopharynx
- At some places, this lymphoid tissue is aggregated to form masses.

Components

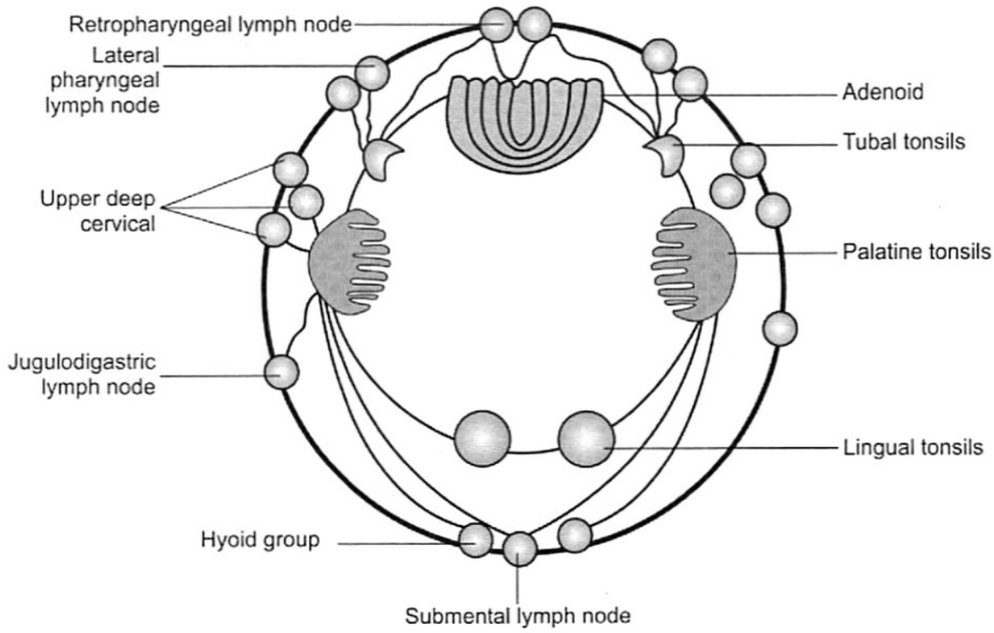

Figure 1: Waldeyer's ring—components

Components	*Location*
a. Palatine tonsils	• In palatine fossa between anterior and posterior pillars of fauces in lateral wall
b. Nasopharyngeal tonsil (adenoids)	• At junction of roof and posterior wall of nasopharynx in midline
c. Tubal tonsils	• In fossa of Rosenmuller behind opening of Eustachian tube
d. Lingual tonsil	• Upper surface of posterior 1/3rd of tongue, one on each side and continues with lower ends of palatine tonsils
e. Lateral pharyngeal bands	• Descend from tubal tonsil, behind posterior faucial pillars
f. Pharyngeal nodules	• In subepithelial layer of posterior pharyngeal wall

Features

- Lymphoid tissue of Waldeyer's ring exhibit efferent vessels but no afferents
- They drain into upper deep cervical lymph nodes
- Waldeyer's ring changes with age, i.e. lymphoid tissue is small at birth and increases till age of 8–10 years (physiological hypertrophy) followed by gradual receding in size to become steady by 20 years of age.

Importance (Functions)

- Act as first line of defence by way of localization of infection and development of immunity against invading organism by
  - Formation of lymphocytes and plasma cells
  - Antibody formation in early years of life
  - Protecting lower respiratory tract by guarding entry of air passage
  - Continuous monitoring of different types of invading microorganism.

7. Etiology, clinical features and management of adenoiditis.

- Chronic inflammation or enlargement of adenoids is called adenoiditis.
- Also called adenoid hypertrophy or adenoids.

Etiology		Predisposing factors
Physiological	Pathological (Causative organisms)	
• Generalized lymphoid hyperplasia	• *H. influenzae* • Streptococci (group A beta hemolytic) • Staphylococci • Moraxella catarrhalis • *Mycobacterium tuberculosis* (rare)	• Recurrent attacks of rhinitis, sinusitis or chronic tonsillitis • Allergy of upper respiratory tract • Low socioeconomic status • Overcrowding, environmental pollution

Clinical Features

- Usually affects children aged between 3-10 years.

	Symptoms	Signs
Nasal	• Nasal obstruction – Commonest symptom – Leads to mouth breathing, snoring – Interferes with feeding or suckling a child • Persistent nasal discharge (Anterior and postnasal) – Wet bubbly nose – Due to choanal obstruction and associated chronic rhinitis • Recurrent sinusitis – Chronic maxillary sinusitis due to persistence of nasal discharge and infection • Epistaxis (Due to nose blowing) • Voice change – Toneless voice with loss of nasal quality (rhinolalia clausa)	• Mucoid or mucopurulent nasal discharge • Mucosal congestion and edema • Decreased fogging on both sides on cold spatula test
Aural	• Recurrent attacks of earache (Due to infection and blockage of Eustachian tube) • Ear discharge (Due to serous otitis media) • Deafness (Due to blockage of Eustachian tube)	• Retracted or bulging tympanic membrane (depending upon severity) • Conductive hearing loss on tuning fork test • Fluid levels
Throat (Naso-pharyngeal)	• Recurrent sore throat (Due to mouth breathing) • Painful swallowing (Due to recurrent pharyngitis or tonsillitis)	• Post nasal discharge • Enlarge mass of adenoids on posterosuperior wall of nasopharynx • Mucosal congestion • Granular posterior pharyngeal wall
General	• Malnutrition (Due to feeding and breathing cannot occur simultaneously • Nocturnal enuresis (Due to suffocation because of nasal obstruction)	• Adenoid facies – Characteristic facial appearance in long standing case of adenoiditis • Cause – Chronic nasal obstruction and mouth breathing • Features – Elongated face with dull idiotic expression – Open mouth with mouth breathing – Prominent and crowded upper teeth – Hitched up upper lip – Loss of nasolabial fold – Pinched in appearance of nose (due to disuse atrophy of alae nasi) – Highly arched palate – Deafness • Pulmonary hypertension • Cor pulmonale • Pigeon shaped chest • Growth retardation • Failure to thrive

Investigations

Diagnostic nasal endoscopy	X-rays
• To assess degree of hypertrophy and compromise in nasopharyngeal airway	• Lateral view of neck reveals size of adenoids and extent of compromised nasopharyngeal air space

Differential Diagnosis

a. Nasal obstruction due to other causes like rhinitis, sinusitis, antrochoanal polyp

b. Orthodontic abnormality
   - High arched palate with protruding teeth
   - No nasal obstruction

c. Thornwaldt's disease
   - Seen in adults
   - Midline cyst in nasopharynx because of persistence of median furrow of adenoids.

Treatment

Conservative

Indications	Techniques
• Less marked symptoms	• Breathing exercise • Systemic antibiotics to control infection • Decongestant nasal drops and orally to reestablish nasal breathing • Antihistaminics

Operative Techniques

Adenoidectomy

Indications	Contraindications
• Adenoid hypertrophy with marked symptoms • Recurrent rhinosinusitis • Aural conditions associated with adenoiditis • Chronic secretory otitis media or benign CSOM causing recurrent ear discharge • Dental malocclusion (prevents recurrence)	• Cleft palate or submucus palate (results in palatopharynge insufficiency) • Age under 3 years • Cervical spine pathology • Bleeding diathesis • Acute infection of upper respiratory tract

Anesthesia	Position
• General anesthesia with endotracheal intubation	• Supine with extended head in neutral position by placing pillow under shoulders and head stabilized by rubber ring under it (Rose's position)

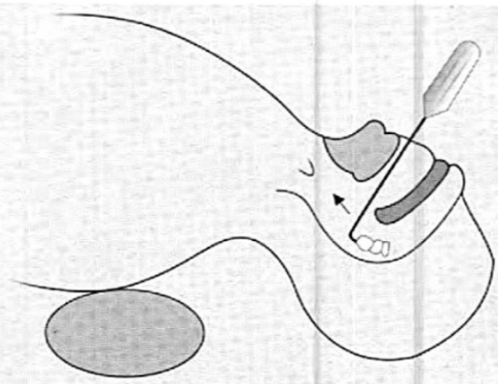

Figure 2: Adenoidectomy

Procedure

- Insert mouth gag
- Examine nasopharynx (by retracting soft palate with curved end of tongue depressor) to confirm diagnosis, asse size of adenoids and push lateral adenoid masses towards midline
- Insert St. Clair Thomson adenoid curette with guard (of proper size) into oropharynx with blade pointing laterally ar then rotated 90° to enter nasopharynx
- Bring its free edge in contact with posterior border of nasal septum and then pressed backwards to engage adenoi
- While engaging adenoids slightly flex head to avoid injury to odontoid process
- Shave off adenoids with gentle downward and forward sweeping movement across roof and posterior wall nasopharynx
- Remove lateral masses with smaller curettes and tags of lymphoid tissue with punch forceps
- Hemostasis achieved by postnasal packing with gauze under pressure or electrocautery in persistent bleeders.

Postoperative care	Complications	
	Immediate	Delayed
• Watch for vitals and bleeding from nose and mouth • Antibiotics and analgesics for a week • Maintain oral hygiene • Soft or liquid diet for 2days and shifting gradually to solid food	i. Hemorrhage • Primary hemorrhage – Due to partial removal of adenoids – Fills nose and mouth with blood – Usually stops after complete removal or tags and postnasal packing • Reactionary hemorrhage – Due to incomplete removal of adenoid tissue or excessive curetting of nasopharynx – Indicated by rising pulse rate – Controlled by postnasal pack, ligation or electrocoagulation of bleeding vessels ii. Injury to surrounding structures • Injury to Eustachian tube opening, uvula and soft palate • Injury to pharyngeal musculature (due to undue pressure of curette) • Subluxation of atlantoaxial joint (due to hyperextension of neck)	i. Secondary hemorrhage (rare) • Due to infection • Indicated by vomitus of dark colored blood swallowed in postoperative period • Treated by rest and antibiotics ii. Velopharyngeal insufficiency iii. Nasopharyngeal stenosis (due to scarring) iv. Otitis media (due to fibrosis of Eustachian tube opening) v. Chronic nasopharyngitis vi. Nasal voice (rhinolalia aperta) vii. Recurrence (due to growth of remnant adenoid tissue)

1. How will you diagnose and manage a case of juvenile nasopharyngeal angiofibroma?

- Juvenile nasopharyngeal angiofibroma is rare but most common benign tumor of nasopharynx.

Etiopathogenesis (Theories of Origin)

Fibroblastic theory	*Hormonal theory*	*Hamartomatous theory*	*Other theories*
Suggests abnormal growth from certain nasopharyngeal tissues like fascia basalis, embryonic occipital cartilage or periosteum of nasopharyngeal wall	Suggest imbalance between estrogen and androgen	Suggest origin from nasal erectile tissue on stimulation by testosterone	Suggest causes, such as trauma, inflammation, infection, allergy and heredity

Site of Origin

- Fibrovascular stroma on posterolateral wall of nasal cavity close to superior margin of sphenopalatine foramen.

Pathology

Gross appearance	*Microscopic examination*
• Pink or red smooth, firm, uncapsulated mass with lobulated surface	• Tumors shows great vascularity with multiple sinusoidal spaces of variable sizes • Primitive embryonic vessels lined by flattened epithelium devoid of muscular wall • Stroma appear as loose connective tissue, highly cellular with some collagen fibers and fibroblasts

Spread

- Tumor lacks definitive capsule and invades locally
- Earliest spread is medially into nasal cavity and nasopharynx
- Laterally, it extends into pterygopalatine fossa where it erodes posterior wall of maxilla to enter maxillary sinus and then involves infratemporal fossa via pterygomaxillary fissure
- Posteriorly, it may destroy median and lateral pterygoid plates
- Anteriorly, it spreads into orbit and through pterygopalatine fossa into maxillary sinus
- Superiorly, into sphenoidal sinus through sphenopalatine foramen
- Intracranial spread occurs thorugh spheniodal sinus involving cavernous sinus, sella and middle cranial fossa.

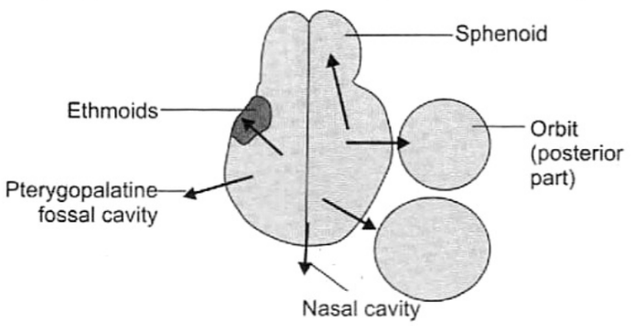

Figure 1: Juvenile nasopharygeal angiofibroma—spread

Clinical Features

- Exclusively seen in adolescent males in 2nd decade of life.

Symptoms	*Signs*	
	Early stage	*Late stage (due to spread)*
• Progressive increasing blocking of nose • Recurrent profuse, painless epistaxis • Nasal discharge	• Rhinolalia clausa (due to nasal obstruction by tumor) • Pink or red smooth globular mass with lobulated surface and dilated blood vessels on surface in posterior part of nasal cavity between middle turbinate and septum on rhinoscopy • Nasal septum pushed to opposite side • Bulging of soft palate (due to large mass in late stage) • Marked anemia (due to repeated blood loss) • Underdeveloped secondary sexual characteristics	• Middle ear problems like conductive hearing loss, serous otitis media, tinnitus, recurrent otalgia (due to blocking of Eustachian tube) • Frog face deformity (proptosis, broadening of nose and swelling of cheek) • Eye problems like eye pain, lacrimation, diplopia, etc. • Affection of 2nd to 6th cranial nerves (due to involvement of cavernous sinus)

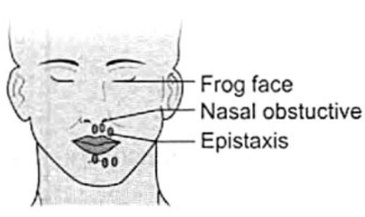

Clinical features

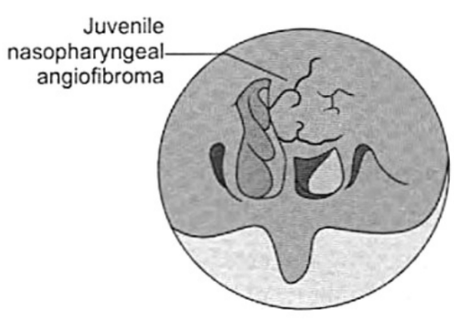

Indirect laryngoscopy

Figure 2: Juvenile nasopharygeal angiofibroma

Investigations

a. Radiography
   - X-ray shows soft tissue shadow in nasopharynx and forward displacement of posterior wall of maxilla (on lateral view)
   - Water's view shows displacement of nasal septum, opacification of sinuses, widening of distance between maxilla and mandible (if extended into cheek)
   - Anterior bowing of maxilla and posterior bowing of pterygoids (Holman-Miller sign)—Pathognomonic
   - CT scan demonstrates extent of tumor, bony destruction and increased vascularity of tumor
   - MRI useful in intracranial or orbital extensions.

b. Angiography
   - External carotid angiography to demonstrate increased vascularity and feeding vessel (tumor blush).

c. Biopsy
   - Avoided due to risk of severe hemorrhage
   - Excision biopsy preferred.

Staging (Fisch classification)

- Stage I Tumors limited to nasal cavity, nasopharynx with no bony destruction
- Stage II Tumors invading pterygomaxillary fossa, paranasal sinuses with bony destruction
- Stage III Tumors invading infratemporal fossa, orbit and/or parasellar region remaining lateral to cavernous sinus
- Stage IV Tumors invading cavernous sinus, optic chiasmal region and/or pituitary fossa

Differential Diagnosis

Infected antrochoanal polyp	*Nasopharyngeal carcinoma*
• Grey, pale polypoidal mass in nasophyarnx • No history of epistaxis	• Friable, proliferative or ulcerated mass • High incidence of lymph node metastases

Treatment

Conservative

Hormonal therapy	*Chemotherapy*	*Radiotherapy*
• Doubtful value *Indications* • Patients unfit for surgery • Adjuvant to radiotherapy *Drugs* • Diethylstilboestrol and flutamide	*Indications* • Recurrent tumors • Residual tumor mass *Drugs* • Doxorubicin, vincristine and dacarbazine	• To reduce vascularity *Indications* • Intracranial extension • Recurrent tumors • Patients unfit for surgery *Schedule* • 3000–3500 cGY in 15-18 fraction in 3–3½ weeks

Operative

- Excision
  - Treatment of choice.

  Preoperative preparation
  - Blood grouping and cross-matching along with provision of 2–3 pints of blood for transfusion if needed
  - Reduce vascularity of tumor by:
    - Cryotherapy
    - Embolization of external carotid artery
    - 2.5 mg Stilboestrol TID for 3 weeks

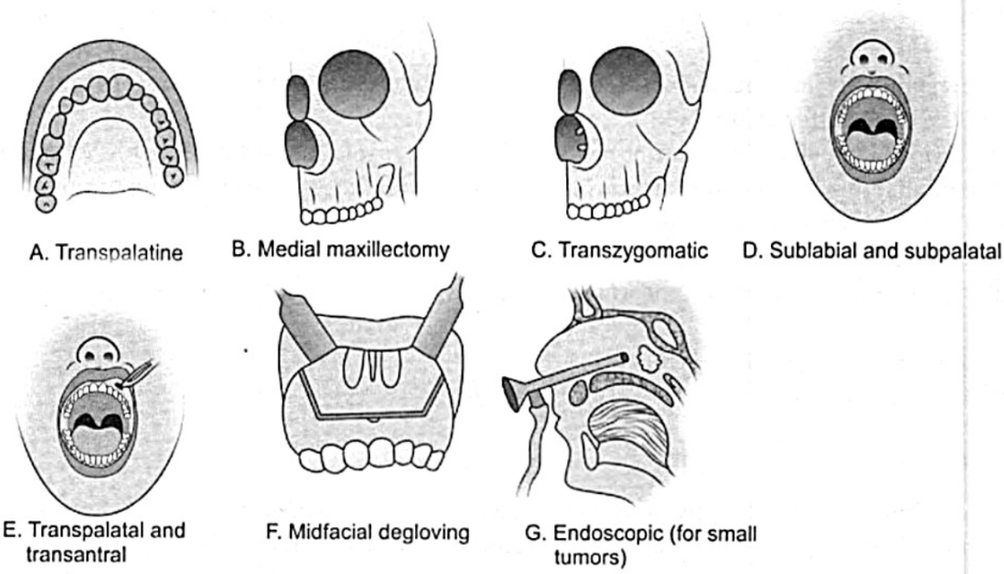

Figure 3: Juvenile nasopharygeal angiofibroma—surgical approach

Techniques

i. Wilson's transpalatal approach

Indications

- Tumors limited to nasopharynx.

Procedure

- Make a U-shaped incision in coronal plane about 2.5 cm anterior to junction of soft and hard palate
- Remove part of hard palate for better exposure
- Incise mucoperiosteum around tumor mass
- Separate tumor from its base with strong periosteal elevator.

Disadvantages

- Risk of oronasal fistula.

ii. Lateral rhinotomy approach with medial maxillectomy

Indications

- Extension into maxillary sinus.

iii. Transpalatal with Denker's modification of Caldwel-Luc operation

Indications

- Extension into maxillary antrum.

iv. Biller's approach

Indications

- Very large tumor with multiple extensions.

Procedure

- Transmandibular lip splitting to give excellent exposure of infratemporal fossa, pterygoid muscles.

Disadvantages

- External scar.

Prognosis

- Good if completely excised.

Clinical Features

- Usually seen after 60 years of age.

Symptoms	Signs
• Dysphagia (prominent feature), appears after a few swallows when pouch gets filled with food and presses on esophagus • Gurgling sound on swallowing • Halitosis, transfer dysphagia (difficulty initiating swallowing) • Voice changes due to overflow of sac contents into larynx causing chemical irritation and laryngitis or due to pressure of sac on recurrent laryngeal nerve • Regurgitation of undigested food at night (when patient is recumbent) causing cough and chocking • Aspiration pneumonia	• Weight loss and malnourishment due to dysphagia • Swelling on left side of neck in anterior triangle, which is soft and gurgles on palpation (Boyce sign) • Associated with hiatus hernia • Rarely malignant transformation (in long-standing cases)

Investigations

- Barium swallow to demonstrate the sac and its size.

Treatment

Operative

- Diverticulectomy (excision of pouch) or cricopharyngeal myotomy or both—through cervical approach
- Endoscopic division of partition wall between esophagus and pouch (dilatation of cricopharyngeal sphincter)
  - Dohlman's procedure—using diathermy (indicated in high risk or debilitated patients)
  - Laser treatment—using CO_2 laser under operating microscope.

LONG ESSAYS

1. Discuss etiopathology, clinical features and management of carcinoma nasopharynx.

- Nasopharyngeal carcinoma is a multifactorial disease uncommon in India.

Etiology

Causative agent	*Predisposing factors*
• Epstein-Barr virus	a. Genetic susceptibility – Common in people from southern China, Taiwan, Indonesia, Hong Kong – In India, common in people of mongoloid origin, i.e. residents of North East India b. Environmental – Air pollution – Smoke from burning incense and wood c. Diet – Consumption of dry salted fish (contains nitrosamines) – Smoked food d. Personal habits – Smoking of tobacco and opium

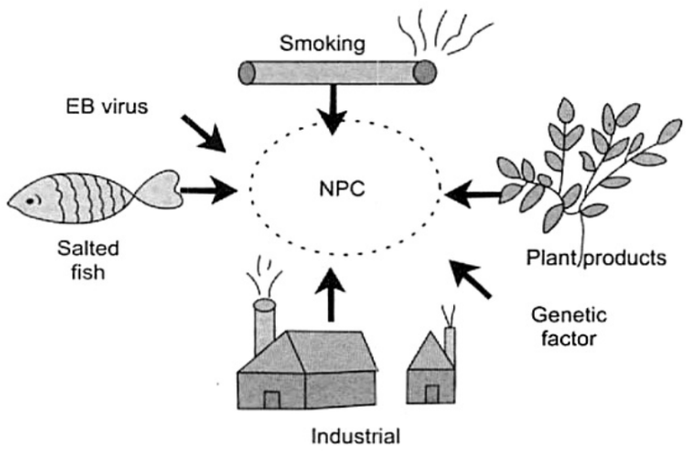

Figure 1: Nasopharyngeal carcinoma—predisposing factors

Pathology (types)

Gross Appearance

i. Proliferative type — Polypoid tumor filling up nasopharynx
ii. Ulcerative type — Tumor mass with ulceration
iii. Infiltrative type — Tumor invades submucosa

Histopathology (WHO)

i. Type I (25%) — Squamous cell carcinoma
ii. Type II (12%) — Nonkeratinizing carcinoma (with/without lymphoid stroma)
iii. Type III (63%) — Undifferentiated carcinoma (with/without lymphoid stroma)

Site of Origin

- Fossa of Rosenmuller in lateral wall of nasopharynx (commonest site)
- Posterosuperior wall.

Spread

Direct spread to	*Lymphatic spread to*	*Distant metastases to*
• Cranium through foramen lacerum and ovum involving cranial nerves III, IV, V and VI • Parapharyngeal space involving cranial nerves IX, X, XI and XII along with pterygoid muscles • Eustachian tube, nose and orbit	• Retropharyngeal nodes and cervical nodes	• Liver, lungs and bone (spine)

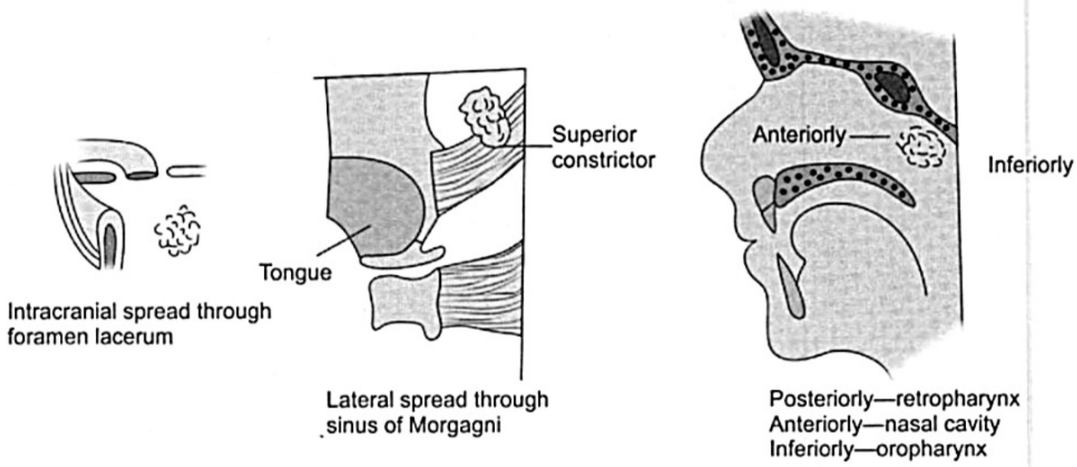

Figure 2: Nasopharyngeal carcinoma—spread

Clinical Features

- Seen mostly in males in their 5th–7th decades

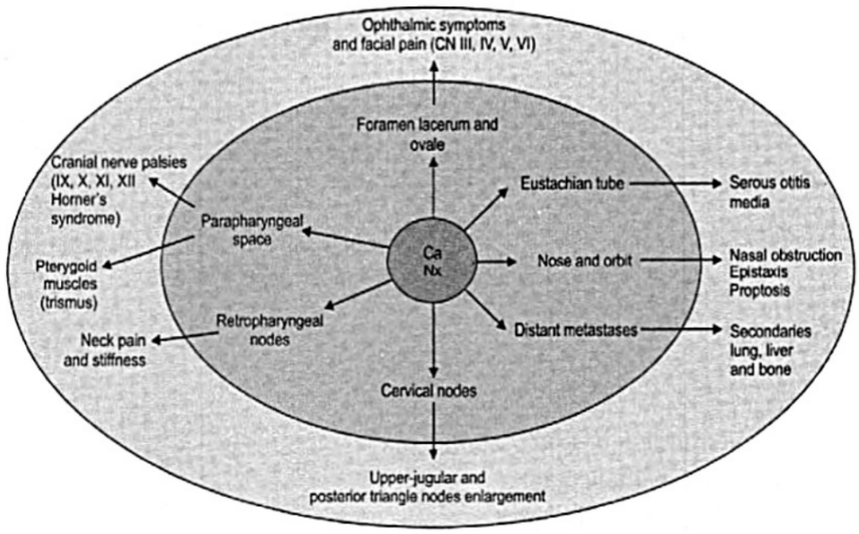

Figure 3: Nasopharyngeal carcinoma—spread and clinical features

Nasal	*Otological*	*Opthalmoneurological (due to involvement of cranial nerves)*	*General*
• Nasal obstruction • Nasal discharge • Denasal speech • Epistaxis	• Ear discharge (mostly unilateral) • Hearing loss • Tinnitus and dizziness	• Diplopia • Headache • Facial and neck pain • Blindness (due involvement of II nerve at apex of orbit)	• Loss of appetite • Weight loss • Lump in neck • Difficulty to open mouth

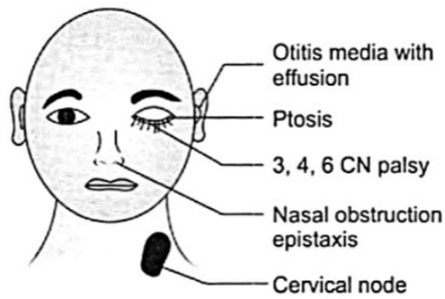

Figure 4: Nasopharyngeal carcinoma—clinical features

Signs

Cervical lymphadenopathy—(Most common)	*Nasal*	*Otological*	*Ophthalmoneurological*
• Bilateral enlargement of lymph nodes between angle of jaw and mastoid process and some along spinal accessory in posterior triangle of neck	• Rhinolalia clausa	• Conductive deafness • Serous or suppurative otitis media	• Reduced corneal reflex (due to invasion of V nerve through foramen lacerum) • Squint and ophthalmoplegia (due to involvement of III, IV and VI nerves) • Exophthalmos • Palatal palsy (due to involvement of X nerve) • Trismus (due to involvement of pteryogids) • Jugular foramen syndrome (due to pressure of lateral retropharygeal lymph nodes or direct involvement of IX, X and XI nerves) • Horner's syndrome (due to involvement of cervical sympathetic chain) • Trotter's triad (triad of conductive deafness, ipsilateral temporoparietal neuralgia and palatal palsy)

Investigations

a. Radiology
   - X-rays (skull) and CT scan to demonstrate erosion of bone at base of skull and extent of tumor
   - MRI with gadolinium enhancement to reveal intracranial extension.

b. Biopsy
   - Endoscopic or operative (through transpalatal approach).

TNM Staging

Stage	Tumor growth	Nodal involvement	Metastases
X	—	Cannot be assessed	Cannot be assessed
0	—	No regional node metastasis	No distant metastases

Contd...

Contd...

Stage	Tumor growth	Nodal involvement	Metastases
1	Confined to nasopharynx	Unilateral metastasis; above supraclavicular fossa; 6 cm or less	Distant metastasis
2	Extended to oropharynx and/or nasal cavity	Bilateral metastasis; above supraclavicular fossa; 6 cm or less	—
2a	Without parapharyngeal extension		
2b	With parapharyngeal extension		
3	Invasion of bony structures and/or paranasal sinuses	Metastasis in lymph nodes	—
3a		>6 cm	
3b		In supraclavicular fossa	
4	Intracranial extension and/or involvement of cranial nerves, infratemporal fossa, hypopharynx or orbit or masticator space	—	—

Treatment

Chemotherapy	Radiotherapy (treatment of choice)	Operative
Indications • In combination with radiotherapy (concomitantly or post-radiotherapy) *Regime* • Cisplastin with/without 5-FU *Advantages* • Doubles cure rate when combined with radiotherapy • Improves local control of tumor • Treats distant metastases	• External or intracavitary implants (brachytherapy) *Regime* • 6000–7000 rads using large ports externally over period of 6 weeks	• Radical neck dissection for persistent nodes • Skull base surgery of recurrent tumor

Prognosis

- Good (>5 years) if diagnosed and treated early.

16. Keratosis pharyngitis.

- Benign self-limiting condition
- Also called tonsillar keratosis.

Etiopathogenesis

Etiology	Pathology
• Idiopathic	• Hypertrophy and keratinization of overlying epithelium

Clinical Features

Symptoms	Signs
• Irritation and mild discomfort in throat • Bad taste in mouth • Feeling of foreign body	• Horny outgrowth on surface of tonsil, pharyngeal wall, lingual tonsil or base of tongue appearing as white or yellowish dots • Firmly adherent lesions which cannot be easily removed • No accompanying inflammation

Differential Diagnosis

- Acute follicular tonsillitis.

Treatment

- Spontaneously regresses within few months
- No specific treatment except reassurance
- Mandl's paint and gargles if necessary.

CHAPTER 51: ACUTE AND CHRONIC TONSILLITIS

Long Essays

1. Discuss the etiopathology, clinical diagnosis and management of acute tonsillitis.	374	J13(OS)
2. Enumerate the conditions causing patch on the tonsils and their management.	207	D02, D04
3. Discuss the types, clinicopathological features and management of chronic tonsillitis.	305	J10, D07(OS)

Short Essays

1. Anatomy of palatine tonsil.	127	D15
2. Acute tonsillitis—clinical features and management.	374	D12
3. Membranous tonsillitis.	143	J10(RS2)
4. Differential diagnosis (causes) of a white patch (membrane) on the tonsil.	207	D11(RS2), J16(RS3), J17(RS3), J04, J06, J07, D10(OS)
5. How would you diagnose and treat tonsillar diphtheria?	376	D10
6. Chronic tonsillitis—clinical features (cardinal signs) and management.	305	D06, D13

Short Answers

1. Anatomy of palatine tonsil.	127	D06
2. Lateral relations of tonsils.	128	D11
3. Blood supply of palatine tonsil.	129	D09(RS2), D11(RS2), D07, J12, D12
4. Mention types of acute tonsillitis.	374	D12(OS)
5. Membranous conditions of tonsil.	208	D07(RS2)
6. Cardinal signs of chronic tonsillitis.	305	J15(RS3), J16(RS3), D05
7. Enumerate complications of chronic tonsillitis.	306	D14
8. Tonsillolith.	352	D17(RS3), J13
9. Lingual tonsillitis.	368	D02, J05

22. Signs of chronic tonsillitis.

- Chronic tonsillitis usually results from inadequately treated acute tonsillitis.

Etiopathogenesis

Etiology	*Causative agent*	*Predisposing factors*	*Pathogenesis*
• Recurrent acute tonsillitis • Subclinical tonsillar infections	• β-hemolytic streptococci	• Chronic sinusitis • Chronic dental infection	• Recurrent tonsillitis → minute abscesses within lymphoid follicle → abscess walled of fibrous tissue → surrounded by inflammatory cells → chronic tonsillitis

Types (Pathology)

Chronic follicular tonsillitis	*Chronic parenchymatous tonsillitis*	*Chronic fibroid tonsillitis*
• Tonsillar crypts filled with infected cheesy material appearing as yellowish spots on surface • Occurs usually in adults	• Hyperplasia of lymphoid follicles in tonsillar parenchyma leading to uniform hypertrophy of tonsils with congested and lengthened anterior pillar • Occurs usually in children	• Small but infected tonsils

Clinical Features

- Mostly affects children and young adults.

Symptoms	*Cardinal signs*
• History of recurrent sore throat or acute tonsillitis • Chronic irritation in throat with cough • Bad taste in mouth • Foul breath due to pus in crypts • Thick speech • Difficulty in swallowing • Choking spells in night	• Persistent congestion of anterior pillars (compared to rest of pharyngeal mucosa) • Positive tonsillar squeeze (Ervin-Moore sign) – Expression of purulent cheesy material from tonsillar crypts on pressure on anterior pillar • Nontender enlargement of jugulodiagestric lymph nodes bilaterally (further enlargement and tenderness during acute attack) • Varying degree of tonsillar enlargement (chronic parechymatous type) – Grade I Congested tonsils located within tonsillar fossa – Grade II Hypertrophied tonsils limited to tonsillar brim – Grade III Hypertrophied tonsils extend beyond pillars but not touching each other – Grade IV Tonsils meeting in midline (Kissing tonsils)

- Yellowish beads of pus on medial surface (chronic follicular type)
- Small tonsils but express frank pus or cheesy material on pressing anterior pillar (chronic fibroid type)
- Features of cor pulmonle (long-standing chronic parenchymatous type)

Investigations

Blood investigations	*Microbiological investigations*	*Radiography*	*Diagnostic nasal endoscopy*
• Hemogram, total and differential count, ESR, platelet count, peripheral smear • Bleeding time, clotting time, prothrombin time, activated prothrombin time • Blood grouping	• ASO titer • Throat swab for culture and sensitivity	• X-ray (lateral view of neck) to rule out coexistant adenoid hypertrophy	• To find out any nasal pathology

Treatment

Conservative	*Operative*
• Improvement of general health • Nutritious diet and vitamins • Antibiotics to control infection • Analgesics to relieve pain • Treatment of coexistent infections in nasal and oral cavity	• Tonsillectomy

Complications

- Peritonsillar abscess
- Parapharyngeal abscess
- Intratonsillar abscess
- Tonsilloliths
- Tonsillar crypts
- Septic foci for rheumatic fever, acute glomerulonephritis, ocular and dermatological disorders.

9. Membranous tonsillitis.

- Membranous tonsillitis is a pathological type of acute tonsillitis.

Etiopathogenesis

Causative organism	*Pathogenesis*	*Pathology*
• Hemolytic streptococci • Staphylococci • Pneumococci • *H. influenzae*	• Bacterial infection of tonsil may be primary or secondary to viral infection of upper respiratory tract	• Membrane on tonsillar surface due to coalescing of purulent material which fills tonsillar crypts

Clinical Features

- Common in school going children.

Symptoms	*Signs*
• Sore throat • Difficulty in swallowing • Fever (38–40°C) with chills and rigor • Earache (due to referred pain or secondary otitis media) • Constitutional symptoms like headache, malaise, body aches	• Coated tongue • Foetid breath smell • Hyperemia of pillars, soft palate and uvula • Whitish membrane on medial surface tonsil which could be wiped away with swab • Tender and enlarged jugulodigastric nodes

Investigations

a. Blood investigations	• Cell count reveals leukocytosis
b. Tonsillar swab	• For culture and sensitivity

Treatment

Supportive	*Specific*
	Conservative
• Bed rest and plenty of fluid intake	a. Antibiotics – To control and prevent spread of infection – Penicillin (drug of choice) or erythromycin for 7–10 days b. Analgesics – To relieve local pain and reduce fever

Complications

- Chronic tonsillitis due to recurrent attacks
- Peritonsillar abscess
- Parapharyngeal abscess
- Cervical abscess due to suppuration of jugulodigastric lymph nodes
- Acute otitis media
- Rheumatic fever and acute glomerulonephritis (due to group A beta hemolytic streptococci infection)
- Subacute bacterial endocarditis (due to *Streptococcus viridans* infection).

12. Differential diagnosis of membrane over tonsil.

- Numerous conditions besides tonsillitis manifest with white patch on tonsils because any lesion in oral cavity becomes white due to slough formed by action of saliva on an open wound.

Differential Diagnosis of White Patch on Tonsil

A. Congenital
   - Tonsillar cyst
     - A cyst on tonsil appears like a white patch.

B. Traumatic

Traumatic ulcer	*Foreign body*	*Post tonsillectomy wound*	*Thermal injuries*	*Radiotherapy*
• History of trauma due to tooth brush, pencil held in mouth, fingering in throat • White membrane develops within 24 hours	• Foreign body lodged in tonsillar crypt	• History of tonsillectomy • Absence of tonsils	• History of ingestion of hot food or exposure to chemicals	• Seen in cases with head and neck malignancy treated with radiotherapy

C. Infection

Acute		
a. Bacterial		
Membranous tonsillitis	*Diphtheria*	*Vincent's angina*
• Sudden onset • Fever with chills and rigor • Dysphagia due to severe pain • Exudative membrane over medial surface which can be easily wiped with swab	• Insidious onset • Low or normal temperature • Less local discomfort • Firm, leathery, dirty grey coloured membrane extending beyond tonsil on to soft palate • Strongly adherent and leaves behind bleeding surface when removed • Markedly enlarged lymph nodes • Microbiological studies reveal *Corynebacterium diphtheria*	• Insidious onset • Less fever and less discomfort • May be unilateral or bilateral • Grayish necrotic membrane covering tonsil or pharyngeal mucosa • Can be easily removed revealing deep irregular ulcer • Microbiological studies reveal fusiform bacilli or spirochetes
b. Viral		
Herpes	*Infectious mononucleosis*	
• Extremely painful • Gray membrane surrounded by red halo • Single or multiple ulcers in row • Heals spontaneously	• Affects young adults • Marked local discomfort • Tonsils enlarged, congested and covered with membrane • Splenomegaly and enlarged lymph nodes in posterior triangle of neck • Failure of antibiotic regime • Lymphocytosis with atypical lymphocytes • Paul-Bunnell test shows high titre of heterophile antibody	
c. Fungal		
Thrush		
• Seen in infants in debilitated people • Milky white, curd-like patches • Discrete, slightly raised • Removable leaving behind inflamed base		
Chronic		
Tuberculosis	*Syphilis*	
• Severe pain • Secondary to pulmonary infection • Multiple white patches over tonsil	• Snail track ulcer on tonsils, pillars, palate and pharyngeal wall • History of primary chancre	

D. Blood dyscriasis

Agranulocytosis	*Leukemia*
• Severely ill patient • Ulcerative necrotic lesion in oropharynx besides tonsil • Decreased total leucocyte count (<2000/cu mm)	• Increased total leucocytic count (>100,000/cu mm) • Associated with progressive anemia • Blast cells in bone marrow smear

E. Malignancy

Benign	*Malignant*
• Papilloma presents white patch over tonsil	• Hard irregular white patch with granulations and everted edge • Bleeds readily on touch

F. Miscellaneous

Aphthous ulcer	*Tonsillar keratosis*	*Tonsillolith*	*Tonsillar cyst*
• Involve any part of oropharynx • Very painful • Variable size	• Whitish horny outgrowth • Adherent at base • Recurs after removal	• Hard whitish patch projecting from cysts	• Yellowish white colour membrane projecting from cysts • Single or multiple

Arterial supply	*Venous drainage*	*Lymphatic drainage*	*Nerve supply*
a. Main – Tonsillar branch of facial artery b. Additional – Ascending palatine branch of facial artery – Dorsal lingual branches of lingual artery – Ascending pharyngeal branch of external carotid artery – Greater palatine branch of maxillary artery	• Through one or more veins leaving lower part of lateral surface into palatine, pharyngeal or facial veins	• Into jugulo – digastric nodes	• Glossopharyngeal and lesser palatine nerves

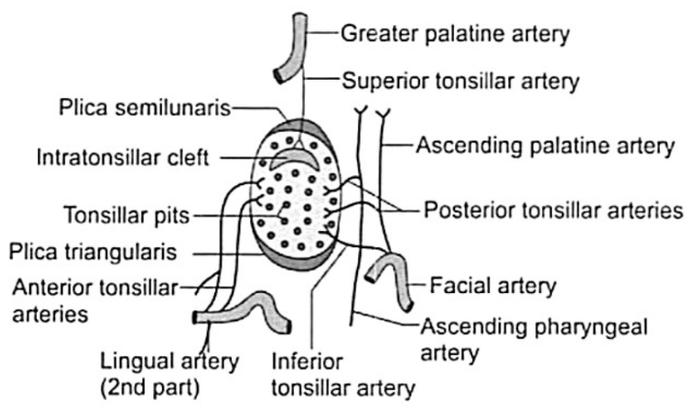

Figure 19: Palatine tonsil—arterial supply

18. Tonsilloliths.

- Tonsilloliths (Tonsollith) is presence of calculus (stone) in the crypts of tonsil
- Also called as Tonsillar concretions.

Etiopathogenesis

- Seen as complication of chronic tonsillitis when its crypt is blocked with retention of debris
- Inorganic salts of calcium and magnesium are then deposited leading to formation of a stone.

Clinical Features

- More often seen in adults
- Usually affects upper pole of tonsil.

Symptoms	*Signs*	*Diagnosis*
• Local discomfort or foreign body sensation	• Unilateral enlargement of affected tonsil • Halitosis and sore throat (due to bacterial growth in retained material) • Whitish foul-tasting and foul-smelling cheesy material expressed from tonsil	• Palpation or gritty feeling on probing

Treatment

Conservative	*Operative*
• Expression of concretions/cheesy material and chemical cauterization of crypts with topical silver nitrate application	• Simple removal of the stone • Tonsillectomy (if associated persistent pain, sepsis or deeply set stone)

Complications

- Stone may gradually enlarge and then ulcerate on medial surface of tonsil.

CHAPTER 52: HEAD AND NECK SPACE INFECTIONS

Long Essays

1. Enumerate the ENT conditions presenting with trismus. Discuss the etiopathology, clinical features and management of peritonsillar abscess (Quinsy).	319, 180	D03, J17
2. Discuss the etiopathology, clinical features and management of deep neck space infections.	105	D09(RS2)
3. Describe the anatomy of retropharyngeal space. Discuss the etiopathogenesis, clinical features and management of (acute) retropharyngeal abscess.	105	D14(RS3), J07, J09(OS)
4. Name the two types of retropharyngeal abscess. Describe the etiology, pathogenesis, clinical features and treatment of any one of them.	106	D00

Short Essays

1. Ludwig's angina.	198	D11(RS2), D15(RS3), D17(RS3), J01, J13, D00(OS), D11(OS)
2. Peritonsillar abscess (quinsy)—define, etiopathogenesis, clinical features and management.	180	J11(RS2), J14(RS3), D15(RS3), D16(RS3), J01, D01, J02, J08, D08, D10, J12, J00(OS), J01(OS), J03(OS), D05(OS), J07(OS), J10(OS), D11(OS), J13(OS), J14(OS)
3. Retropharyngeal abscess—etiology and management.	106	J08(RS2), J14(RS3), J09
4. Acute retropharyngeal abscess—etiology, clinical features and management.	107	D13(RS3), D08, D11, J12, D16(OS)
5. Chronic retropharyngeal abscess.	107	J16(RS3), D02
6. Tuberculous cervical lymphadenitis.	363	J07, J14
7. Parapharyngeal space (anatomy and its surgical approaches).	106	J17(RS3), J02(OS), D08(OS)
8. Parapharyngeal space abscess.	108	D14, D15

Short Answers

1. Ludwig's angina.	198	D10(RS2), J16(RS3), J17(RS3), D05, J09, D99(OS)
2. Peritonsillar abscess (quinsy).	180	D07(RS2), J16, D16, D01(OS), J02(OS), D02(OS)
3. Space of Gillette.	106	D01, J02, J05
4. Acute retropharyngeal abscess.	107	D16
5. Parapharyngeal space.	106	D12(RS3), J03
6. Parapharyngeal abscess.	108	J10

2. Discuss the etiopathology, clinical features and management of deep neck space infections.

- Deep neck spaces are potential spaces between layers of cervical fascia.
- Of many deep neck spaces, spaces of clinical importance are:
  i. Retropharyngeal space
  ii. Parapharyngeal space

Anatomy

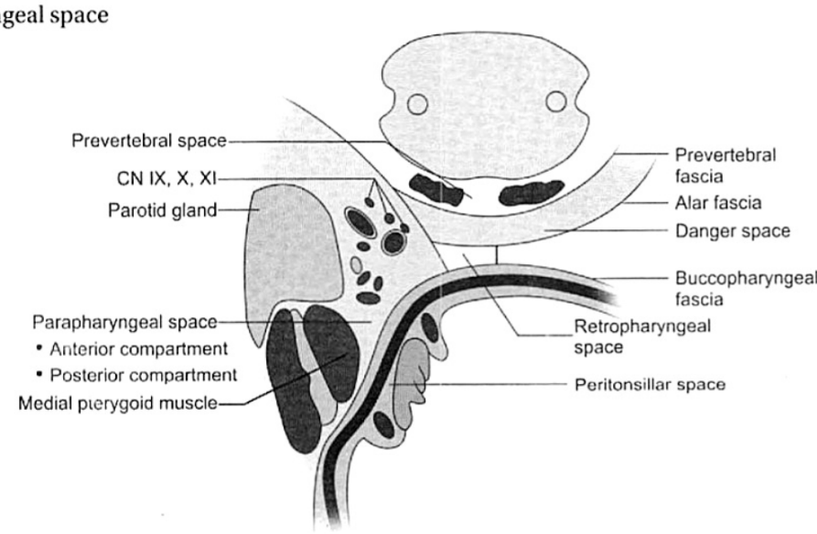

Figure 4: Deep spaces of neck—anatomy

	Retropharyngeal space	*Parapharyngeal space*
Synonyms	Posterior visceral space Retroesophageal space Retrovisceral space Space of Gillette Lincoln's highway (for spread of infection to mediastinum)	Pharyngomaxillary space Lateral pharyngeal space
Boundaries		
Anterior	Buccopharyngeal fascia	Interpteryoid fascia Pterygomandibular raphe
Posterior	Alar fascia	Prevertebral fascia Posterior aspect of carotid sheath
Lateral	Carotid sheath Parapharyngeal space	Superficial layer of deep cervical fascia Medial pterygoid muscle Mandible Deep surface of parotid gland
Medial	Midline septum (dividing it in to 2 spaces)	Middle layer of deep cervical fascia Fascia of tensor and levator muscles of velum palatine Styloglossus
Superior	Base of skull	Base of skull
Inferior	Extends into superior mediastinum	Hyoid bone
Contents	Loose areolar tissue and fat Lymph nodes draining adjacent structures	• Prestyloid compartment Loose areolar tissue and fat Lymph nodes Internal maxillary artery • Poststyloid compartment Carotid artery Jugular vein Cranial nerves IX, X, XI and XII Sympathetic trunk

Deep Neck Space Infections

A. Retropharyngeal abscess

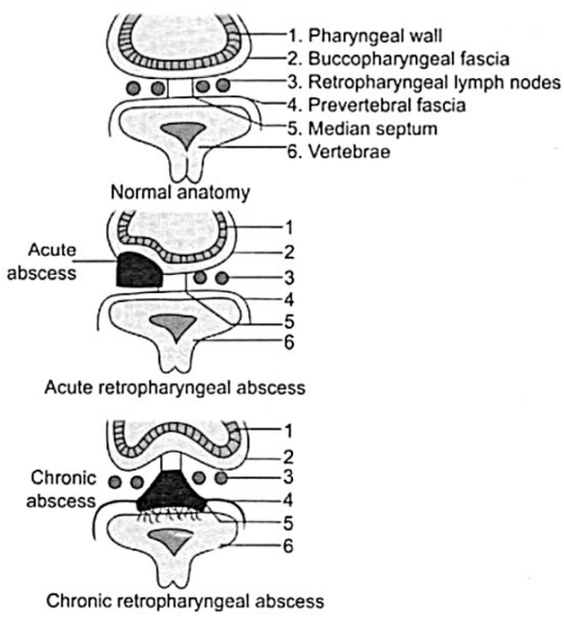

Figure 5: Retropharyngeal abscess

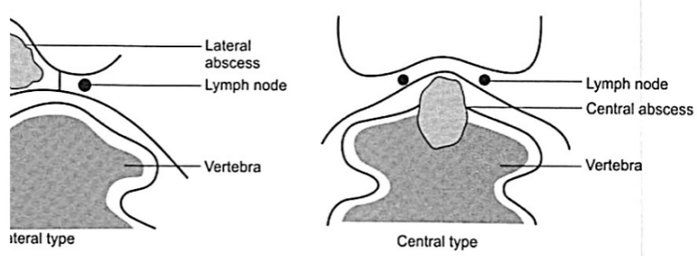

Figure 6: Chronic retropharyngeal abscess—types

	Acute retropharyngeal abscess	Chronic retropharyngeal abscess
	• Very painful condition due to suppuration of retropharyngeal lymph nodes	• Chronic tuberculous infection of retropharygeal lymph nodes Types a. Lateral type – Due to tuberculous infection of retropharyngeal lymph nodes – Presents unilateral swelling on right or left side of midline – Usually affects children aged 8–10 years b. Central type (more common) – Due to cold abscess of cervical spine – Presents midline swelling spreading to both sides – Affects any age group
Etiology		
Causative organism	• *Streptococcus* • *Staphylococcus*	• *Mycobacterium tuberculosis*
Source of infection	• Secondary to infections of adenoids, nasopharynx, sinuses, nasal cavity (in children) • Penetrating injury to posterior pharyngeal wall or cervical esophagus (in adults) • Spread of pus from acute mastoiditis	• Cold abscess of cervical spine • Tuberculous infection of retropharyngeal lymph nodes secondary to tuberculosis of deep cervical nodes
Clinical features	• Commonly seen in boys below 3 years of age	• Insidious onset • Systemic features of tuberculosis
Symptoms	• Difficulty in breathing and eating (due to obstruction of air and food passage by abscess) • Croupy cough • Voice like quacking of a duck • Constitutional symptoms like fever, toxemia	• Discomfort in throat • Difficulty in swallowing (not marked) • Painless lump in throat
Signs	• Unilateral swelling in posterior pharygenal wall (on one side of midline) • Soft, fluctuating swelling extending upwards toward nasopharynx and downwards into cricopharynx but never crossing midline • Glossy inflamed mucosa • Dribbling and pooling of saliva • Torticollis • Trismus • Stridor • Acute lymphadenitis of jugulodigestric lymph nodes or lymph nodes in upper part of posterior triangle	• Fluctuant swelling on posterior pharyngeal wall located centrally (due to cervical spine caries) or one side of midline (due to tuberculous lymph nodes) • No signs of acute inflammation • Torticollis
Investigations	a. Radiology (X-ray, CT and MRI) – Lateral view of neck shows widening of prevertebral shadow and presence of fluid level and gas – Increased distance between laryngotracheal air column and anterior border of cervical vertebra (at C2 >7 mm and at C6 >14 mm in children and >22 mm in adults)	a. X-rays – Lateral view reveals caries of spine and soft tissue shadow of abscess b. Tuberculin test – Positive c. Bacteriological examination of pus – Reveals mycobacteria
Differential diagnosis	• Cold abscess of retropharyngeal lymph nodes • Cold abscess of vertebral column	

	Acute retropharyngeal abscess	Chronic retropharyngeal abscess
Treatment		
Supportive	a. Tracheostomy – In cases of large abscess causing mechanical obstruction to airway or laryngeal edema	
Conservative	• Systemic antibiotics to control infection • Analgesics to relive pain and control inflammation • Steroids for impending laryngeal edema • Nutrition	• Antitubercular treatment (Full course as per RNTCP)
Operative	a. Incision and drainage Anesthesia – Nil Position – Supine with head low Incision – Vertical incision in most fluctuant area of abscess Procedure – Open mouth with gag and incise abscess – Drain abscess with suction (prevent aspiration of pus) Postoperative – Suitable antibiotic cover for 7–10 days	a. Incision and drainage – Vertical incision along border of sternomastoid (anterior border for low abscess or posterior border for high abscess) and drainage with suction b. Aspiration – Aspiration of abscess with thick needle through oral cavity under cover of antibiotics and antitubercular drugs
Complications	• Laryngeal edema requiring tracheostomy • Dehydration due to diminished fluid intake • Spontaneous rupture leading to sudden death due to inhalation of pus	

B. Parapharyngeal abscess
- Suppuration of parapharyngeal space due to spread of infection from adjacent structures.

Etiology

Spread of infection from	External trauma
• Pharynx—Acute and chronic infections of tonsils and adenoids, bursting of peritonsilar abscess • Teeth—Infection of lower last molar teeth • Ear—Bezold's abscess, petrositis • Other spaces—Parotid, retropharyngeal and submaxillary space infections	• Penetrating injury to neck • Injection of local anesthetics for tonsillectomy or mandibular nerve block

Clinical features
- Common in young adults.

Symptoms	Signs
• Fever • Painful swallowing • Sore throat and pain	• Torticollis • Toxemia *Anterior compartment infections* • Prolapse of tonsil and tonsillar fossa • Trismus (due to spasm of medial pterygoid muscle) • Swelling behind angle of jaw *Posterior compartment infections* • Swelling of pharynx behind posterior pillar • Paralysis of IX, X, XI, XII cranial nerves and sympathetic chain • Swelling of parotid region

Differential diagnosis
- Peritonsillar abscess (quinsy)
- Retropharyngeal abscess
- Tumors
- Aneurysms.

Treatment

Conservative	Operative
• Systemic antibiotics intravenously to control infection • Analgesics to relieve pain and control inflammation	a. Incision and drainage *Anesthesia* – General *Incision* – Horizontal incision, 2–3 cm below angle of mandible *Procedure* – After incision, carry out blunt dissection along inner surface of medial pterygoid towards styloid process – Evacuate abscess and retain a drain

Complications

- Acute edema of larynx with respiratory obstruction
- Thrombophelbitis of jugular vein with septicemia
- Spread of infection to retropharyngeal space
- Spread of infection to mediastinum along carotid space
- Mycotic aneurysm of carotid artery (due to weakening of vessel wall)
- Carotid blow out with massive hemorrhage.

5. Ludwig's angina.

- Ludwig's angina is infection of submandibular space with cellulitis and occasional abscess formation
- Submandibular space lies between mucus membrane of floor of the mouth and tongue on one side and superficial layer of deep cervical fascia between hyoid bone and mandible on other side and is divided into sublingual and submaxillary and submental spaces by mylohyoid muscle.

Etiology

Causative agents	*Source of infection*
• Streptococci (alpha hemolytic) • Staphylococci • Bacteroides	• Dental infection (80%), especially of lower 2nd and 3rd molars • Submandibular sialadenitis • Infection or injuries of oral cavity • Lingual tonsillitis • Infection following dental extraction • Fracture of mandible

Clinical Features

- Common in age group of 20–50 years.

Symptoms	*Signs*
• Painful swallowing • Fever • Salivation	• Trismus of varying degree • Swelling of structures in the floor of the mouth • Tongue pushed upward and backward threatening to block airway • Tender brawny swelling of submandibular region with woody hard feel • Stridor due to laryngeal edema

Investigations

- Radiography
  - Dental X-ray to assess dental status
  - CT scan to know extent of disease.

Differential Diagnosis

- Acute submandibular sialadenitits
- Acute cervical lymphadenitis
- Infected plunging ranula
- Infection of necrotic tumor mass
- Tumors or granuloma of submandibular gland.

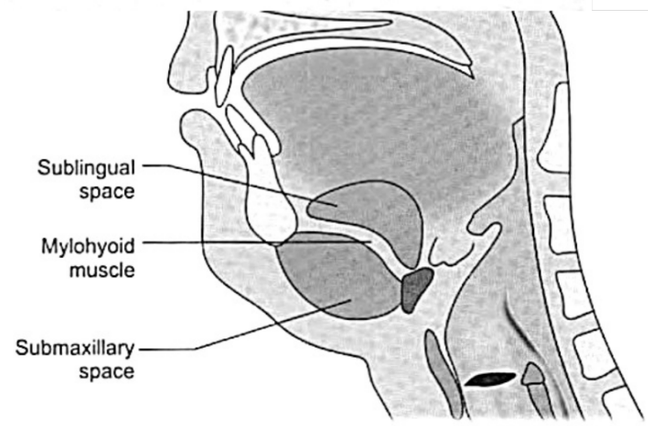

Figure 5: Ludwig's angina

Treatment

Supportive	*Conservative*	*Operative*
• Tracheostomy – In cases of threatened airway blockage	• Broad spectrum systemic antibiotics along with metronidazole • Anti-inflammatory drugs along with serratiopeptidase	• Incision and drainage – Intraoral incision at point of maximum fluctuation (if infection localized to sublingual space) – External transverse incision 2 finger breadth below mandibular margin from one angle of mandible to another over area of induration along with vertical opening of midline musculature of tongue with blunt hemostat (if infection involves submaxillary space) followed by retaining drainage tube or antibiotic soaked ribbon gauze and allowing incision to heal by secondary intention

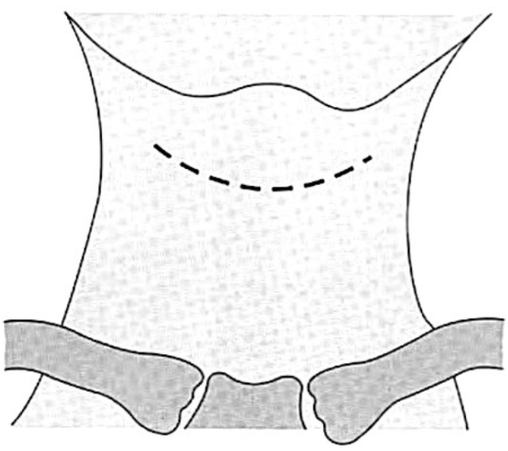

Figure 6: Ludwig's angina—incision

Complications

- Spread of infection to parapharyngeal and retropharyngeal space and thence to mediastinum
- Airway obstruction due to tongue pushed back or laryngeal edema
- Tongue necrosis
- Septicemia
- Aspiration pneumonia.

7. Clinical features and management of peritonsillar abscess.

- Collection of pus in peritonsillar space (outside tonsillar capsule and medial to superior constrictor muscle) is called peritonsillar abscess or quinsy.

Types

Anterior presentation (MC)	*Posterior presentation*	*Lingual*	*Tonsillar*
Abscess points through anterior pillar	Abscess pushes tonsil forwards	Affects lower pole of tonsil	Abscess within tonsil

Etiopathogenesis

Causative agents	*Predisposing factors*	*Pathogenesis*
• *Streptococcus pyogens* • *Staphylococcus aureus* • Pneumococci • Anaerobic organisms	• Recurrent tonsillitis (usually as a sequel) • Foreign body embedded in tonsilar substance • Tonsilloliths or cyst • Dental infection like periodontitis • Inflammation of Weber gland (accessory salivary gland just above superior pole in soft palate)	Recurrent tonsillitis ↓ Fibrosis of mouths of tonsillar crypts (esp. cysta magna) ↓ Bacterial infection of tonsils ↓ Edema and fibrotic stenosis of mouth of crypts ↓ Sealing of tonsillar crypts ↓ Formation of intratonsillar abscess ↓ Bursting of abscess through tonsillar capsule ↓ Peritonsillitis ↓ Peritonsillar abscess

Pathology

- Fibrosis of intratonsillar crypts.

Clinical Features

- Usually seen in adult males aged 20–50 years
- Mostly unilateral but occasionally bilateral.

Symptoms	*Signs*
• Unilateral pain in throat, aggravated on swallowing • Painful swallowing (odynophagia) → saliva dribbling from angle of mouth • Muffled and thick speech (hot potato voice) • Foul breath (due to sepsis in oral cavity) • Earache on same side (referred pain via 9th cranial nerve) • Difficulty in opening mouth (due to spasm of pterygoid muscles) • Constitutional symptoms like fever, chills and rigor, general malaise, body aches, headache, nausea and constipation	• Congestion and swelling of tonsils, pillars and soft palate on involved side • Swollen, elongated and edematous uvula pushed to opposite side • Bulging of soft palate and anterior pillar above tonsil • Tonsils pushed medially and downwards • Tonsillar region covered with mucopus • Purulent fetid discharge if abscess is ruptured • Enlarged jugulodigastric lymph nodes • Trismus • Torticollis towards side of abscess

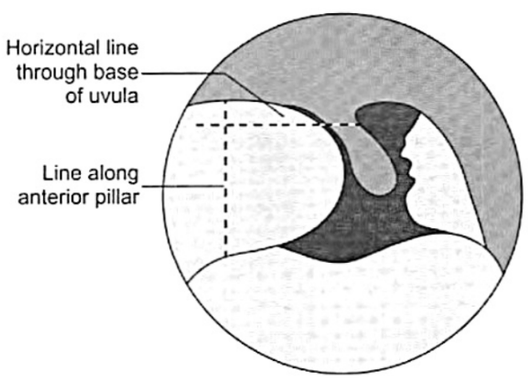

Figure 1: Peritonsillar abscess—signs

Investigations

Blood investigations	Blood sugar	Culture and sensitivity	CT scan
• Indicates septicemia	• To rule out diabetes mellitus	• To identify causative organism and its antibiotic sensitivity	• To determine extent of abscess and presence of parapharyngeal abscess if any

Differential Diagnosis

Acute tonsillitis	Retropharyngeal or parapharyngeal abscess	Malignancy of tonsils (Lymphoepithelioma)
• Bilateral • Less severe pain • No radiating pain to ear		• More chronic • Less pain • Hard to feel • No pus on incision

Treatment

Supportive	Conservative	Operative
• Hospitalization and bed rest • Parenteral nutrition • Oral hygiene by regular mouth wash by H_2O_2 or saline • Analgesics to relieve pain and reduce fever	a. Antibiotics – IV infusion of broad spectrum antibiotics	a. Incision and drainage (described below) b. Tonsillectomy *Procedures* i. Abscess or hot tonsillectomy - Removal of tonsils including abscess *Disadvantages* - Risk of rupture of abscess during anaesthesia - Excessive bleeding ii. Interval tonsillectomy - Removal of tonsils after 4–6 weeks following remission

- Incision and drainage (most preferred)

  Indications
  - Formation of frank abscess

  Anesthesia
  - Local anesthesia with 4% lignocaine
  - General anesthesia with precautions in uncooperative children

  Incision (any of the following)

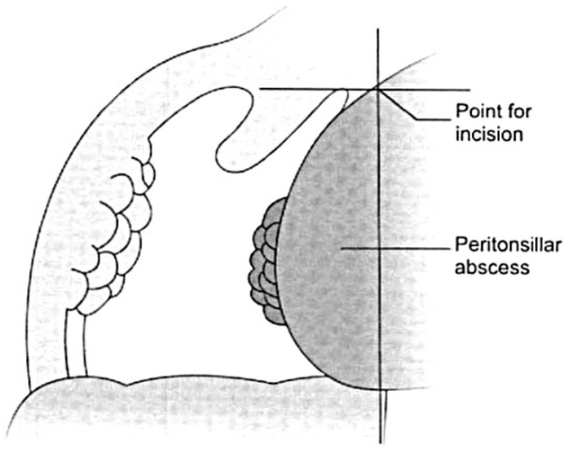

Figure 2: Peritonsillar abscess—point of incision

  - On point of maximum bulge above upper pole of tonsil
  - At intersection of imaginary horizontal line drawn through base of uvula and vertical line along base of anterior pillar
  - Through intratonsillar cleft.

  Procedure
  - Make a small stab incision with quinsy forceps or a guarded knife (guarded by winding adhesive tape at distance of 1 cm from its tape)
  - Insert a sinus forceps during the procedure to open and drain abscess and may be done on following day to drain any reaccumulations.

  Follow-up
  - H_2O_2 gargles
  - Antibiotics and analgesics.

Complications (of quinsy)

- Parapharyngeal abscess
- Supraglottic edema
- Septicemia
- Peumonitis or lung abscess
- Jugular vein thrombosis or phlebitis
- Spontaneous hemorrhage from carotids or jugular due to necrosis.

CHAPTER 53: TUMORS OF OROPHARYNX

Short Essays

1. Etiology of oropharyngeal cancer.	35	J08(RS2)
2. Eagle's syndrome.	147	J10(RS2), D08, J05(OS)

Short Answers

1. Mention the risk factors of cancer oropharynx.	35	J16(OS)
2. Elongated styloid process (Eagle's syndrome).	147	D14(RS3), J02, D11, J10(OS)

CHAPTER 54: TUMORS OF THE HYPOPHARYNX AND PHARYNGEAL POUCH

Short Essay

1. Post-cricoid malignancy.	33	J08(RS2)

CHAPTER 55: SNORING AND SLEEP APNEA

Short Essay

1. Obstructive sleep apnea syndrome.	144	J10(RS2), D10(RS2), D12(RS3), D14(RS3), J17

Short Answer

1. Sleep apnea.	144	D09(RS2), J13

7. Etiology of oropharyngeal cancer.

- Oropharyngeal cancers may be benign (papilloma) or malignant (sqaumous cell carcinoma).

Etiology

Causative agents	*Predisposing factors*
a. Tobacco – Tobacco chewing or smoking accounts for 2/3rd of oropharyngeal cancers – Reverse smoking (keeping burning end of cigarette in mouth) practiced in India also may cause oropharyngeal cancer b. Alcohol – People consuming alcohol along with tobacco consumption are at 15 time greater risk – Tobacco and alcohol act synergistically c. Premalignant conditions – Premalignant conditions like leukoplakia, erythroplakia or submucous fibrosis may turn malignant	a. Age – Common after 4th decade b. Sex – Females are 6 times more prone c. Race – Blacks are twice as prone as whites

12. Eagle's syndrome.

- Also called styalgia, elongated styloid process.

Etiology

- Elongated styloid process
- Angulated styloid process
- Calcification of stylohyoid ligament.

Clinical Features

- May be unilateral or bilateral.

Symptoms		*Signs*
Classical type	*Styloid process—carotid artery syndrome*	
• Dull or intermittent pain in throat and upper neck radiating to ipsilateral ear (due to glossopharyngeal neuralgia) • Pain aggravated on swallowing • Difficulty in swallowing • Foreign body sensation in throat	• Parietal headache (due to disturbance in circulation) • Pain along distribution of artery involved (due to irritation of nerve plexus around vessels)	• Tenderness in tonsillar fossa • Palpable elongated styloi process in tonsillar fossa

Investigations

- X-ray (AP view with open mouth and lateral view of skull)
  - Reveals elongated styloid process.

Treatment

Conservative	*Operative*	
• Analgesics to relieve pain	Excision of styloid process	
	↓	↓
	Transoral approach (treatment of choice)	Cervical approach
	• Tonsillectomy followed by exposure of styloid process in tonsillar fossa • Excise elongated portion of styloid process after elevating periosteum around it	• Incise along anterior border of sternomastoid from tip o mastoid till hyoid bone • Retract anterior border and expose styloid process b deep dissection • Excise elongated portion of styloid process after elevatin periosteum around it

10. Sleep apnea syndrome.

- Sleep apnea is at least 30 apneic episodes each lasting for 10 seconds or more during a bout of sleep lasting for 7 hours.

Types

Central	*Obstructive*	*Mixed*
• No airflow and no respiratory effort • Breathing resumes again due to stimulation of respiratory centers by hypoxia • Repeating cycle of breathing and apnea throughout sleep	• No airflow despite respiratory effort • Due to upper respiratory tract obstruction • Seen exclusively in males • Associated with loud snoring and abnormal movements during sleep	• Combination of failure of central control and upper airway obstruction

Etiology

Etiology			*Predisposing factors*
Physiological	*Anatomical*	*Pathological*	
	• Macroglossia • Subtle reduction in airway size • Retrognathia	• Deviated nasal septum (DNS) • Nasal polyposis • Adenotonsillar hypertrophy • Laryngeal edema • Malignancy of upper respiratory tract • Myxedema • Chronic obstructive pulmonary disease (COPD)	• Obesity • Alcohol intake • Drugs

Pathogenesis

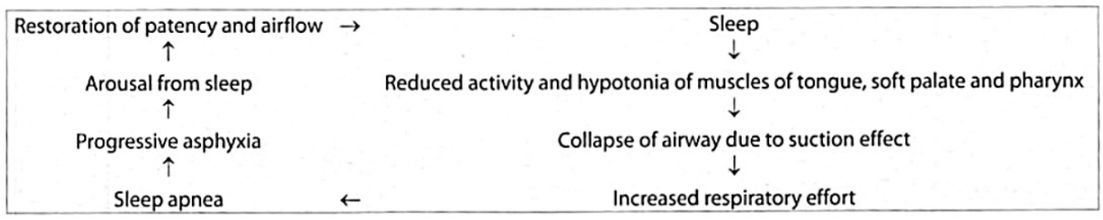

Clinical Features

- Occurs at any age but increased incidence after 40 years
- Common in males.

Symptoms	*Signs*
• Snoring (due to narrowing of airway during sleep) • Nocturnal asphyxia • Frequent arousal from sleep • Morning headaches • Day time sleepiness • Nocturnal enuresis and impotence	• Snoring • Features of airway obstruction • Obstructive lesion of upper respiratory pathway

Investigations

- Polysomnography (detailed examination during sleep with monitoring of sleep stage
- Transcutaneous monitoring of O_2 saturation during sleep
- Pulmonary function tests
- X-ray and CT of nose and pharynx to diagnose site of obstruction
- Diagnostic nasal endoscopy
- Muller's maneuver
- Multiple sleep latency test.

Treatment

Supportive	*Specific*	
	Conservative	*Operative*
• Weight reduction • Cessation of alcohol and drug • Physiotherapy	• Continuous positive airway pressure ventilation • Prosthetic devices to retain tongue in forward position	a. Nasal or nasopharyngeal surgery – In cases with nasal or nasopharyngeal obstruction b. Adenotonsilectomy – In cases with obstruction due to hypertrophied tonsils or adenoids c. Uvulopalatopharyngoplasty (using laser or radiofrequency waves) – Excision of tonsils, pillars, uvula and ring of posterior part of soft palate d. Tracheostomy – In extreme cases

Complications

- Pulmonary or systemic hypertension
- Mental dysfunction and personality disorder
- Myocardial infarction, stroke
- Cardiac arrhythmias, heart failure, death.

5. Postcricoid malignancy.

- Constitutes 30% of laryngopharyngeal malignancies.

Etiology	*Predisposing factors*
• Plummer Vinson syndrome	• Betel nut chewing • Smoking

Pathology

Gross appearance	*Microscopic examination*
• Ulcerative type of lesion	• Moderately differentiated squamous cell carcinoma

Spread

- Local spread (annular fashion) involving cervical esophagus, arytenoids or recurrent laryngeal nerve at cricoarytenoid joint
- Lymphatic spread to paratracheal lymph nodes bilaterally.

Clinical Features

- Usually affects females in 3rd and 4th decade of life.

Symptoms	*Signs*
• Progressive dsyphagia • Progressive malnutrition • Weight loss • Voice change and aphonia in later stages (due to infiltration of recurrent laryngeal nerve or posterior cricoarytenoid muscle)	• Loss of laryngeal crepitus • Edema and erythema of postcricoid region • Pooling of secretions in hypopharynx

Investigations

Radiography	*Endoscopy (direct laryngoscopy)*
• X-ray (lateral view of neck) shows increased prevertebral shadow • Barium swallow to assess extent of disease	• To assess extent of lesion and take biopsy

Treatment

Radiotherapy	*Operative*
Dose • 5000–6000 rads of cobalt 60 over 5–6 weeks *Advantages* • Preserves laryngeal function	• Laryngo-pharyngo-esophagectomy with stomach pull up or colon transposition

Prognosis

- Poor due to early bilateral lymphatic metastases and vertebral column involvement.

SECTION V: DISEASES OF LARYNX AND TRACHEA

CHAPTER 56: ANATOMY AND PHYSIOLOGY OF LARYNX

Long Essay

1. Discuss the physiology of phonation.	30	J08(RS2)

Short Essays

1. Intrinsic muscles of larynx.	31	J08(RS2)
2. Differences between adult and infant's larynx.	89	J09(RS2), D11(RS2), D15
3. Functions of larynx.	242	D12(RS3)
4. Describe the mechanism of phonation.	30	D10(OS)

Short Answers

1. Laryngeal cartilages .	96	J09(RS2)
2. Unpaired cartilages of larynx.	96	D11, J06(OS)
3. Tensors of the vocal cords.	32	D06(OS)
4. Differences between adult and infant larynx.	89	D10(RS2)
5. Functions of larynx.	242	I10(RS2), D14

CHAPTER 57: LARYNGOTRACHEAL TRAUMA

Long Essay

1. Discuss the etiopathology, clinical features and management of laryngotracheal trauma.	307	D15(RS3)

CHAPTER 58: ACUTE AND CHRONIC INFLAMMATIONS OF LARYNX

Short Essays

1. Acute epiglotitis (clinical features and management).	35	J08(RS2), D17(RS3), D12
2. Laryngeal diphtheria.	376	D14
3. Tuberculosis of larynx.	377	J15

Short Answers

1. Epiglottitis in children.	35	D00, D04
2. Acute epiglottitis.	35	D01(OS)
3. Management of acute epiglotitis.	36	D14(RS3)
4. Reinke's edema.	150	J10(RS2), J11(RS2), D16(RS3), D14
5. Features of tubercular laryngitis.	377	J09

2. Discuss the physiology of phonation.

- Phonation means production of sound which is a function of larynx acquired during evolution.

Principle

- Phonation is based on Bernoulli's effect which states that during steady flow of a fluid or a gas, pressure is less where velocity is greater
- Thus, when air passes from lungs to pharynx through a constriction, i.e. glottis, velocity of air would be greatest and pressure least at site of constriction.

Mechanism (Aerodynamic Myoelastic Theory)

- When we wish to phonate, recurrent laryngeal nerve sets vocal cords into adducted position, but because vocal processes are slightly bulkier than membranous cord, there exists a slight between membranous cords
- When lungs expel air, airstream passes through this chink between vocal cords
- Then according to Bernoulli's principle, there is drop of pressure at vocal cords causing mucosa of vocal cords to be drawn into gap, eventually blocking it
- This causes rise in subglottic pressure forcing another stream of air flow through cords resulting another pressure drop and closure of gap

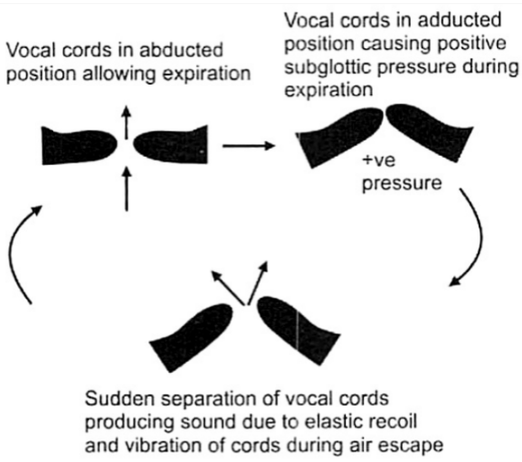

Figure 5: Aerodynamic myoelastic theory

- Repetition of this process develops a vibratory pattern at vocal cords resulting in production of sound
- This sound is modified into speech by tongue, teeth, paranasal sinuses, lip and palate.

Factors Determining Production of Voice

- Pitch is determined by number of vibrations of vocal cord per second depending upon vibratory mass of vocal folds, laryngeal adductors and tensors
- Intensity and duration are determined by capacity of lungs and subglottic pressure build up by adduction of cords
- Quality depends upon resonators and articulators.

5. Adult and infantile larynx.

- Larynx is made up of cartilaginous framework lying in front of hypopharynx.

Comparison of Adult and Infantile Larynx

Points of comparison	*Infant*	*Adult*
a. Size	Smaller	Larger
b. Shape	Funnel shaped with cricoid plate titled backwards (maximum constriction at subglottis)	Tubular
c. Situation	High up, below base of tongue with lower end of cricoid at middle of C6 vertebrae	Lower down in neck with lower end of cricoid at lower border of C6 vertebrae
d. Axis of air entry	Straighter	Curved
e. Submucus tissue	Loose, lax, less fibrous	Less so
f. Lymphatics	Richer	Less so
g. Consistency	Softer and pliable	Hard
h. Epiglottis	Large and often foled onto itself	Not so
i. Cough reflex	Weaker	Stronger
j. Neuromuscular mechanism	Unstable	Stable

Significance

- Greatest choke of infantile larynx at subglottic region predisposes them to stridor
- Due to higher position of infantile larynx, axes of pharynx, larynx and trachea are almost in straight line thus air entry in them is straighter whereas in adult life they meet at more acute angle.

3. Intrinsic muscles of larynx.

- Larynx is an organ for phonation or voice production and communicates above with pharynx and below with trachea.

Intrinsic Muscles of Larynx

- Muscles which are attached to the laryngeal cartilage.

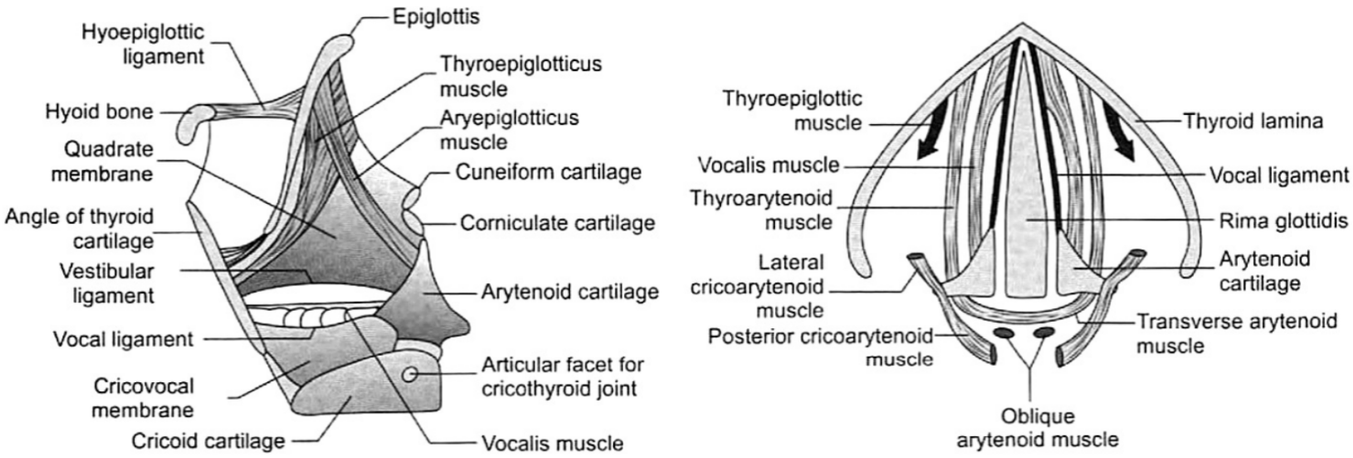

Figure 6: Larynx—intrinsic muscles

Name	Origin	Insertion	Nerve supply	Action
a. Cricothyroid (only intrinsic muscle outside larynx and *only muscle supplied by Ext. laryngeal nerve**)	Lower border and lateral surface of cricoid cartilage	Fibers pass backward and upward to insert into inferior cornu and lower border of thyroid cartilage	External laryngeal	• Closes glottis • Adducts vocal cords • Tenses vocal cords
b. Posterior cricoarytenoid	Posterior surface of lamina of cricoid cartilage	Fibers pass upward and laterally to get inserted into muscular process of arytenoid cartilage	Recurrent laryngeal	• Opens glottis • Abducts vocal cords
c. Lateral cricoarytenoid	Lateral part of upper border of arch of cricoid cartilage	Fibers pass upward and backward to be inserted in to muscular process of arytenoid cartilage	Recurrent laryngeal	• Closes glottis • Adducts vocal cords
d. Transverse arytenoids (Only unpaired muscle)	Posterior surface of one arytenoid cartilage	Fibers runs transversely to insert into posterior surface of opposite arytenoid cartilage	Recurrent laryngeal	• Closes glottis • Adducts vocal cords
e. Oblique arytenoids	Muscular process of one arytenoid cartilage	Fibers runs obliquely across midline crossing each other to be inserted into apex of opposite arytenoid cartilage	Recurrent laryngeal	• Closes inlet of larynx • Relaxes vocal cords
f. Aryepiglotticus	As continuation of oblique arytenoid into aryepiglottic fold	Edge of epiglottic cartilage	Recurrent laryngeal	• Closes inlet of larynx
g. Thyroarytenoid	Posterior aspect of angle of thyroid cartilage and adjacent part of cricothryoid ligament	Fibers run backward and upward to reach anterolateral surface of arytenoid cartilage	Recurrent laryngeal	• Closes glottis • Adducts vocal cords • Relaxes vocal cords
h. Vocalis	As continuation of thyroarytenoid	Vocal ligament	Recurrent laryngeal	• Relaxes vocal cords
i. Thyroepiglotticus	As continuation of thyrocarytenoids	Edge of epiglottis	Recurrent laryngeal	• Opens inlet of larynx

Applied Anatomy

- Damage to external laryngeal nerve causes some weakness of phonation due to loss of tightening effect of cricothyroid on the vocal cords
- When both the recurrent laryngeal nerves are interrupted, vocal cords lie in cadaveric position and phonation is completely lost. Breathing also becomes difficult
- When only one recurrent laryngeal nerve is paralyzed, opposite vocal cord compensates for it and phonation is possible
- In progressive lesion of recurrent nerve, muscles obeys Semon's law which states that in chronic involvement of recurrent nerves, abductors of larynx are paralyzed first, followed by other muscles and on other hand, in functional paralysis of larynx it is vice versa.

12. Functions of larynx.

- Larynx is a musculocartilagenous skeleton connecting pharynx to trachea.

Functions

a. Protection of lower airways
   - Primary and primitive function of larynx is protection of lower airways which is achieved as follows:
     i. Sphincteric closure of laryngeal opening
        * When food is swallowed, three successive sphincters, i.e. laryngeal inlet, false cords and true cords close reflexly, thus preventing entry of food into larynx
        * It is aided by elevation of larynx (mylohyoid), tilting of larynx (stylopharyngeous) and relaxation of cricopharyngeal sphincter.
     ii. Cessation of respiration
        * Contact of food with base of tongue or posterior pharyngeal wall reflexly cease respiration temporarily through afferent fibers of IX nerve.
     iii. Cough reflex
        * Foreign particles which accidently enter respiratory system (larynx) are dislodged and expelled out through a very powerful and protective cough reflex.

b. Phonation (aerodynamic myoelastic theory)
   - In higher animals, larynx is so evolved that it acts like a wind instrument which produces voice by following mechanism.

Adduction of vocal cords
⇓
Generation of infraglottic air pressure by exhaled air due to contraction of thoracic and abdominal muscles
⇓
Vibration of vocal cords due to forced opening of vocal cords by air released as small puffs
⇓
Production of sound which is amplified by mouth, pharynx, nose and chest
⇓
Production of speech by conversion of sound due to modulatory action of lips, tongue, palate, pharynx and teeth

c. Respiration
   - Larynx regulate entry of air into lungs by reflexly adjusting abduction (during inspiration) or adduction (during expiration) of vocal cords.

d. Stabilization of thorax
   - With larynx closed, intrathoracic pressure increases making thorax fixed, thus letting all thoracic and abdominal muscles act best, which is an important feature of various physiological processes like coughing, vomiting, defecation, micturation and parturition besides other strenuous activities like climbing, etc.

13. Laryngeal cartilages.

- **Larynx is organ for production of voice and is made up total 9 cartilages, i.e. 3 paired cartilages and 3 unpaired cartilages.**

Cartilages of Larynx

Unpaired cartilages	*Paired cartilages*
• Thyroid	• Arytenoid
• Cricoids	• Corniculate
• Epiglottic	• Cuneiform

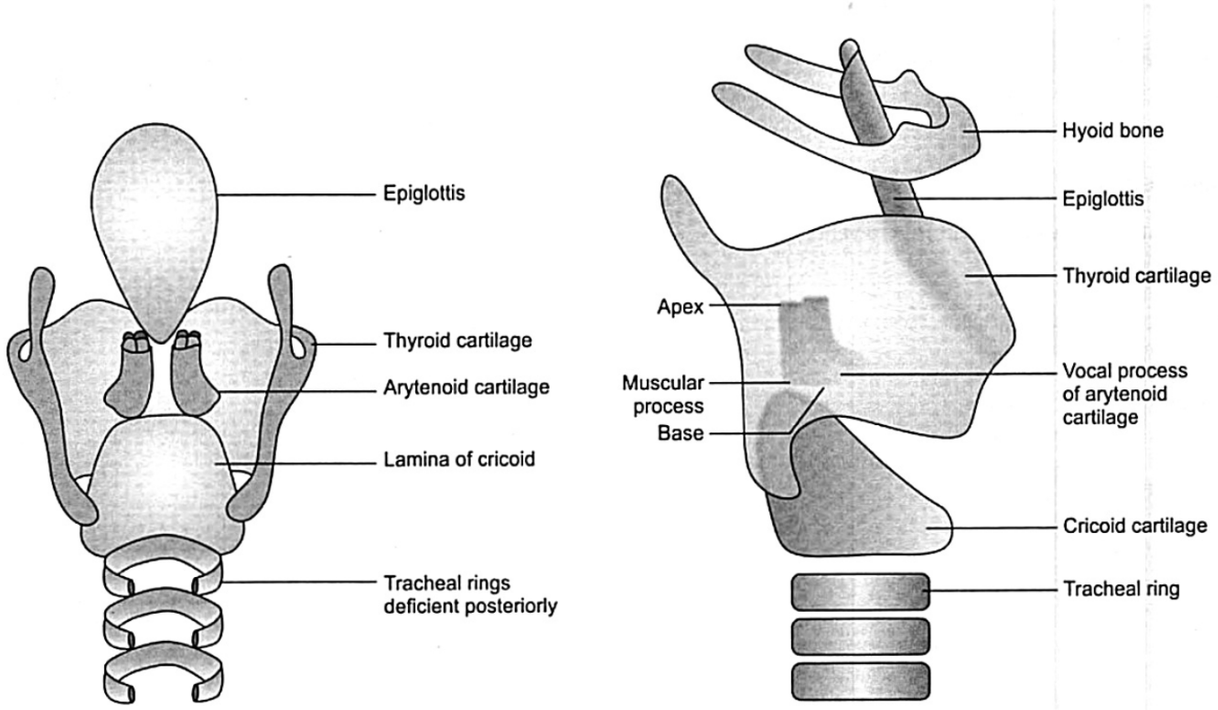

Figure 13: Cartilages of larynx

1. Discuss the etiopathology, clinical features and management of laryngotracheal trauma.

Etiopathology

Etiology	*Pathology*
Blunt injuries • Road traffic accidents (neck striking against steering wheel or front panel)—MC • Blow or kick on neck • Neck hitting against a stretched wire or cable • Strangulation *Penetrating injuries* • With sharp instruments or firearms *Others* • Ingestion of corrosives • Intubation trauma	• Abrasion or contusion on skin • Hematoma and edema of supraglottic or subglottic region • Tears in laryngeal or pharyngeal mucosa → subcutaneous emphysema • Dislocation of cricoarytenoid joints (Arytenoid cartilage may be displaced anteriorly, dislocated or avulsed) • Dislocation of cricothyroid joint → causes recurrent laryngeal nerve paralysis • Fracture (isolated or communited) of laryngeal framework (seen commonly adults above 40 years because of its calcification whereas rare in children due to resilient cartilages) – Fractures of hyoid bone – Fractures of thyroid cartilage (vertical or transverse) – Fracture of upper part results in avulsion of epiglottis and one or both false cords – Fractures of lower part may displace or disrupt true vocal cords – Fractures of cricoid cartilage – Fractures of upper tracheal rings • Separation of trachea from cricoid cartilage and retraction into upper mediastinum → associated with injury to recurrent laryngeal nerve

Clinical Features

Symptoms	*Signs*
• Stridor (due to laryngeal edema or hematoma) • Hoarseness of voice or aphonia • Painful and difficult swallowing; accompanied by aspiration of food, blood and secretion • Local pain in larynx (more marked on speaking or swallowing) • Hemoptysis (from bleeding due to tears in laryngeal or tracheal mucosa)	• Bruises or abrasions of skin • Tenderness of laryngeal area • Subcutaneous emphysema which increases on coughing (due to mucosal tears) • Flattening of thyroid prominence and contour of anterior cervical region with inability to palpate thyroid notch (loss of normal countour of neck) • Fracture displacements of thyroid or cricoid cartilage or hyoid bone • Gap and bony crepitus between fractured fragments of hyoid bone, thyroid or cricoid cartilages may be felt separation of cricoid cartilage from larynx or trachea • There may be other injuries to head, cervical spine, chest, abdomen and extremities

Investigations

a. Indirect laryngoscopy (most valuable investigation)	• Reveals location and degree of edema, hematoma, mucosal lacerations, posterior displacement of epiglottis, exposed fragments of cartilage, asymmetry of glottis or laryngeal inlet
b. Direct laryngoscopy (not routinely done)	• Rarely informative in early period following injury and if performed, may precipitate respiratory distress and necessitate immediate tracheostomy • If required, fibreoptic laryngoscopy is preferred
c. Radiology	
i. X-rays	• Soft tissue lateral X-ray of neck reveals subcutaneous emphysema, swelling of laryngeal mucosa, displacement of epiglottis, fracture displacements of hyoid bone, thyroid and cricoid cartilages or change in configuration of air column • X-ray chest for pneumothorax and gastrografin swallow for esophageal tears
ii. 3D CT scan	• Very valuable in assessing moderately severe or severe injuries of larynx

Treatment

Conservative	*Operative*
• Hospitalize and observe for respiratory distress • Voice rest • Humidification of inspired air • Full dose steroid therapy started immediately (Helps to resolve edema and hematoma and prevent scarring and stenosis) • Antibiotics (to prevent perichondritis and cartilage necrosis)	a. Tracheostomy – Tracheostomy is preferred as endotracheal intubation in these cases may be difficult and hazardous b. Open reduction *Timing* – 3–5 days after injury and not delayed beyond 10 days *Techniques* – Fractures of hyoid bone, thyroid or cricoid cartilage are wired and replaced in their anatomic positions and immobilized using titanium miniplates – Mucosal lacerations repaired with catgut and any loose fragments of cartilage removed – Epiglottis is anchored in its normal position and if already avulsed then excised – Arytenoid cartilages can be repositioned in their normal position or may be removed if completely avulsed – In laryngotracheal separation, end-to-end anastomosis is done – Internal splintage of laryngeal structures is done with a laryngeal stent, or silicone tube and left in-situ for 2–6 weeks – Webbing of anterior commissure can be prevented by a silastic keel

Complications

- Laryngeal stenosis (supraglottic, glottic or subglottic)
- Perichondritis
- Laryngeal abscess
- Vocal cord paralysis.

8. Acute epiglottitis.

- Acute epiglottitis is an acute inflammatory condition of supraglottic region involving epiglottis, aryepiglottic folds and arytenoids
- Also called acute supraglottic laryngitits.

Etiology

Causative Organism

- Hemophilus influenza type B.

Pathology

- Severe cellulitis of epiglottic and aryepiglottic fold tissue
- Congested and edematous mucosa.

Clinical Features

- Usually affects children aged 2–7 years but can also affect adults
- Abrupt onset with rapid progression.

Symptoms	*Signs*
◆ Severe fever (40°) due to septicemia ◆ Pain in throat ◆ Dyspnea and stridor (in children) ◆ Sore throat and dysphagia (in adults) ◆ Muffled (hot potato) voice	◆ Toxic patient with flushed skin, anxious and frightened look ◆ Red and swollen epiglottis (cherry red epiglottis) ◆ Edema and congestion of supraglottic structure ◆ Thick and inspissated secretion ◆ Tripod sign (patient sits up leaning forward supporting on upper limb as inspiratory stridor increases on supine position)

Investigations

Throat swab	*X-ray (lateral view of neck)*
◆ For culture and sensitivity	◆ Shows swollen epiglottis (thumb sign) ◆ Narrowed supraglottic airway

Differential Diagnosis

Acute laryngo-tracheo-bronchitis	*Laryngeal diphtheria*	*Laryngeal*
◆ Seen in children aged 3 months to 3 years ◆ Slow onset ◆ Low grade or no fever ◆ Barking seal like cough ◆ No difficulty in swallowing ◆ Steeple sign on X-ray (AP view) neck	◆ Low grade fever ◆ Croupy cough ◆ Grayish white membrane on tonsil, pharynx and soft palate ◆ Bull neck cervical adenopathy	◆ No cough ◆ Marked respiratory distress ◆ Features of underlying condition

Treatment

Supportive	*Conservative*	*Operative*
◆ Hospitalization ◆ Parenteral fluids for adequate hydration ◆ Humidification and oxygen ◆ Steam inhalation and voice rest	*Antibiotics (combination therapy)* ◆ Ampicillin/amoxicillin ◆ Chloramphenicol (50 mg/kg/day QID) ◆ Ceftrixone (75 mg/kg/day BD) ◆ Cefotaxime (50–100 mg/kg/day QID) *Steroids (to relieve edema)* ◆ Hydrocortisone or dexamethasone parenterally	*Tracheostomy* ◆ For severe respiratory obstruction

Complications

- Otitis media
- Adenititis
- Meningitis
- Pericarditis
- Pneumonia.

20. Reinke's edema.

- Edema of Reinke's space, i.e. subepithelial space of vocal cords
- Also called polypoid degeneration of vocal cords, bilateral diffuse polyposis of vocal cords or localized hypertrophied laryngitis.

Etiology

Etiology	*Predisposing factors*
• Vocal cord abuse	• Heavy smoking • Chronic sinusitis • Laryngopharyngeal reflex • Myxedema

Clinical Features

- Seen in middle age group of 40–60 years
- Common in females.

Symptoms	*Signs (on indirect laryngoscopy)*
• Severe hoarseness of voice • Intermittent aphonia • Low pitched and rough monotonous voice (due to use of false vocal cords)	• Bilateral, symmetrical, spindle shaped fusiform swelling of vocal cord in membranous part • Appear as translucent, grayish pink • Hyperemic and hypertrophied ventricular bands

Treatment

Supportive	*Specific*	
	Conservative	*Operative*
• Voice rest • Cessation of smoking	• Speech therapy	• Decortications of vocal cords by microlaryngosurgery – Stripping of mucosa of vocal cords retaining enough for epithelisation – Done on one side first, followed on other side 1month later to prevent anterior glottic web formation

CHAPTER 59: CONGENITAL LESIONS OF LARYNX AND STRIDOR

Long Essays

1. Define stridor. Enumerate the causes of stridor. How do you manage a patient of stridor?	320	J16(RS3), J03, J11
2. Classify the causes of stridor in a child. Discuss the clinical features and management of juvenile laryngeal papillomatosis.	320, 15	D05

Short Essays

1. Laryngomalacia (congenital laryngeal stridor).	122	D09(RS2), J14, D99(OS)
2. Subglottic stenosis.	369	J17
3. Stridor—define, causes (in children).	320	J14(RS3), D00, D04, J16, D02(OS)

Short Answers

1. Laryngomalacia.	122	D15(RS3), J07, J12, D02(OS), J11(OS)
2. Subglottic stenosis.	369	J01
3. Laryngeal web.	330	J16(RS3), D02, J05, J16
4. Stridor.	320	J12(RS2), J13(RS3), D13(RS3), J13(OS)
5. Etiology of stridor in children.	320	J15(RS3)
6. Enumerate causes of congenital laryngeal stridor.	122	J10

CHAPTER 60: LARYNGEAL PARALYSIS

Short Essays

1. Nerve supply of larynx.	311	D15(RS3)
2. Difference between the right and left recurrent laryngeal nerve anatomy.	130	J05
3. Enumerate the causes of vocal cord paralysis. How do you investigate and manage a case of unilateral vocal cord paralysis.	353	J02, D04
4. Discuss the causes of unilateral vocal cord palsy.	353	D07(OS)
5. Causes of left recurrent laryngeal nerve paralysis.	353	D06
6. What is Dysphagia? Mention the causes of left recurrent laryngeal palsy.	173, 353	J14(OS)

Short Answers

1. Causes of left vocal cord paralysis.	353	J17
2. Recurrent laryngeal nerve.	129	D09(RS2)
3. Bilateral adductor paralysis.	151	J10(RS2)

1. Define stridor. Enumerate the causes of stridor. How do you manage a patient of stridor?

- Stridor is abnormal, harsh, high pitched, turbulent musical breathing sound produced by turbulent airflow through narrowed air passage.

Types

Inspiratory (croup)	*Expiratory (wheeze)*	*Biphasic*
• Seen in obstructive lesions of supraglottis or pharynx • Characterized by low pitched flutter and normal voice	• Seen in lesions of thoracic trachea, primary and secondary bronchi • Characterized by brassy barking cough and normal voice	• Seen in lesions of glottis, subglottis and cervical trachea • Characterized by phonatory stridor and dysphonia

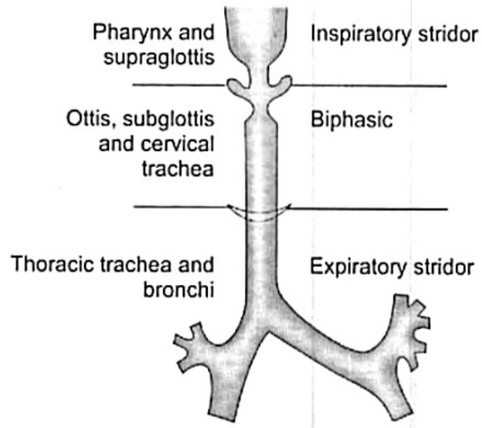

Figure 1: Stridor—types

Etiology

Infants and children		*Adults*
Congenital	*Acquired*	
a. Nose • Choanal atresia b. Tongue • Macroglossia c. Mandible • Micrognathia • Pierre-Robin syndrome d. Pharynx • Congenital dermoid e. Larynx • Supraglottis – Laryngomalacia – Cysts • Glottic – Web	a. Inflammatory • Larynx – Epiglottitis – Laryngotracheitis – Diphtheria • Tracheobronchial – Tracheobronchitis • Outside respiratory system – Ludwig's angina – Retropharyngeal and retroesophageal abscess b. Neoplastic • Hemangioma • Lymphangioma • Thymoma • Juvenile multiple papillomas	a. Trauma • Laryngotracheal trauma and stenosis due to RTA/foreign bodies b. Tumors • Carcinoma larynx • Carcinoma pharynx • Neck masses c. Infection • Tuberculosis • Neck space infections d. Allergy • Angioneurotic edema e. Neurological • Bilateral adductor palsy following thyroidectomy or cardiothoracic surgery

Infants and children		*Adults*
Congenital	*Acquired*	
– Cord paralysis – Cysts • Subglottic – Stenosis f. Tracheobronchial • Atresia • Stenosis • Tracheomalacia g. Outside respiratory system • Vascular rings • Esophageal atresia • Tracheoesophageal fistula • Congenital goiter • Cystic hygroma	c. Traumatic • Laryngeal Injuries like burns, inhalation of fumes or swallowing of corrosives • Foreign bodies • Edema following endoscopy/ intubation • Tracheal stenosis following intubation/ tracheostomy d. Miscellaneous • Dermoid of base of tongue • Lingual thyroid • Laryngeal paralysis due to acquired lesions • Tetanus • Tetany • Laryngismus stridulus	

Clinical Features

- Stridor is physical sign of underlying disease

Symptoms	*Signs*
• Age of onset determines congenital or acquired etiology • May be sudden onset or gradually progressive • Of short duration or long • May be related to feeding • Associated with cyanotic spells • History of aspiration or ingestion of foreign body or laryngeal trauma	• Respiratory distress evident by recession in suprasternal notch, sternum, intercostals spaces and epigastrium • Type and characteristics of stridor indicate location of cause • Inspiratory (supraglottis or pharynx), expiratory (thoracic trachea, primary and secondary bronchi) or biphasic (glottis, subglottis and cervical trachea) • Snoring or snorting sound (nasal or nasopharyngeal cause), gurgling sound and muffled voice (pharyngeal cause), hoarse cry (vocal cord), expiratory wheeze (bronchial obstruction) • Associated fever indicates inflammatory cause • Disappearance of stridor in prone position (laryngomalacia, micrognathia, macroglossia and innominate artery compression)

Investigations

Radiography	*Direct laryngoscopy w/o anesthesia*	*Bronchoscopy, laryngoscopy and esophagoscopy under GA*
• X-ray neck (AP and lateral view) for soft tissue mass in larynx/ hypopharynx, airway patency and prevertebral widening • X-ray chest (PA and lateral view) for pulmonary status, mediastinal widening, secondaries • Fluoroscopy to see chest movements • CT chest to detect mediastinal mass • Esophagogram for atresia, fistula or aberrant vessels • Angiography • Xeroradiography for soft tissue lesions in neck	• To visualize pharynx and larynx and assess possibility of intubation	

Treatment

Supportive	*Specific*
• Hospitalization • Intubation or tracheostomy or cricothyroidotomy to relieve airway obstruction in severe stridor • Oxygen and humidification • Antibiotics and steroids in presence of infection	• Treatment of underlying cause

7. Congenital laryngeal stridor.

- Laryngomalacia is most common congenital anomaly of larynx
- Also called congenital laryngeal stridor because it is most common cause of congenital stridor.

Etiopathogenesis

- Excessive flaccidity of structures bounding supraglottic larynx particularly aryepiglottic fold → sucking in of thes during inspiration → laryngeal narrowing → inspiratory stridor.

Pathology

- Excessive softness, flabbiness or lack of consistency of laryngeal tissue
- Thinning and hypocellularity of laryngeal cartilages
- Wrinkled loose edematous mucosa.

Clinical Features

- Manifests at birth or soon after.

Symptoms	*Signs*
• Stridor, increased on crying or exertion but subsides on placing child in prone position • Cyanosis (sometimes)	• Elongated, tubular epiglottis, curled upon itself (omega-shaped) • Floppy aryepiglottic folds • Prominent arytenoids • Cruciate appearance of laryngeal inlet (due to prolapsed of laryngeal soft tissue into vestibule)



Figure 15: Laryngomalacia

Treatment

Conservative	*Operative*
• Reassurance • Avoid rough handling of children, sudden shocks to them or changes in temperature	• Tracheostomy in severe respiratory obstruction

Prognosis

- Spontaneous regression by 2 years of age.

22 . Laryngeal web.

- Laryngeal web is formation of fibrous tissue covered by epithelium between anterior parts of vocal cords.

Etiopathogenesis	*Site of web*
• Arrest of laryngeal development at 10th week of fetal life resulting in incomplete recanalization of larynx	• Glottis level (75%) • Supraglottic level (25%)

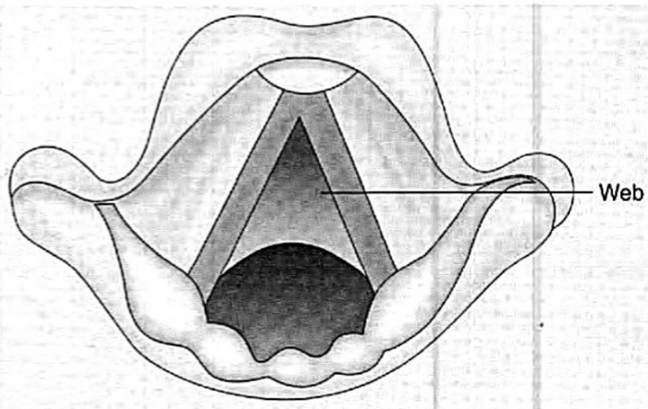

Figure 6: Laryngeal web

Clinical features (Manifests from birth)		*Treatment*	
Symptoms	*Signs*	*Conservative*	*Operative*
• Asymptomatic (if small web) • Stridor (inspiratory) • Weak cry • Aphonia	• White or pink, thick or thin membrane attached anteriorly to both vocal cords with sharp and concave posterior margin	• Reassurance for milder form	• Tracheostomy for severe stridor and dyspnea • Serial microlaryngoscopic dilatation for thin webs • Excision via laryngofissure and placement of McKnought's silicone keel to prevent synechia until cordal reepithelialization occurs for thick webs

7. Nerve supply of larynx.

- Larynx is supplied by vagus through its branches—recurrent laryngeal nerve and internal and external branches of superior laryngeal nerve.

	Recurrent laryngeal nerve	*Superior laryngeal nerve*
Origin and course	Right recurrent laryngeal nerve arises from vagus at level of subclavian artery, hooks around it and then ascends between trachea and esophagus Left recurrent laryngeal nerve arises from vagus in mediastinum at level of arch of aorta, loops around it and then ascends into neck in tracheo-esophageal groove (it has a much longer course making it more prone to paralysis)	Arises from inferior ganglion of vagus, descends behind internal carotid artery and, at level of greater cornua of hyoid bone, divides into external and internal branches
Sensory supply	Below vocal cords	Above vocal cords (internal laryngeal nerve after piercing thyrohyoid membrane)
Motor supply	All muscles of larynx (except cricothyroid)	Cricothyroid

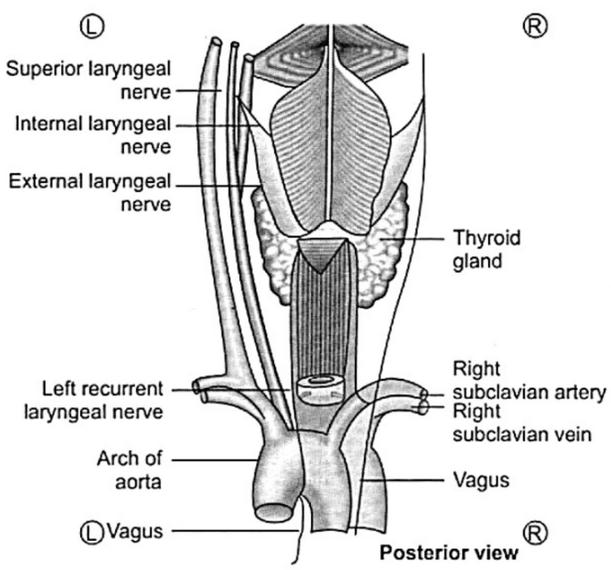

Figure 1: Course of recurrent laryngeal nerve

15. Recurrent laryngeal nerve.

- Recurrent laryngeal nerves are pair of branches of vagus nerve
- They are so called because they take a circuitous route up to thorax and ascend back up in neck to supply larynx.

	Right recurrent laryngeal nerve	*Left recurrent laryngeal nerve*
Origin	• From right vagus infront of right subclavian artery	• From left vagus in thorax when it cross anterior and left surface of arch of aorta
Course	• After origin, nerve winds backwards below subclavian artery and runs upward and medially behind subclavian and common carotid arteries to reach tracheoesophageal groove • In upper part of groove, it is related to inferior thyroid artery either lying superficial or deep to it. Nerve then passes deep to lower border of inferior constrictor and enters larynx behind cricothyroid joint	• After origin, nerve winds round undersurface of arch of aorta, behind and to left side of ligamentum arteriousum and passes upward at first between bifurcation of trachea and aortic arches. As it ascends, it lodges in left tracheoesophageal groove and appears in neck • In neck, it runs medially to left common carotid artery. At lower end of lateral lobe of thyroid gland, it usually lies posterior to loop of inferior thyroid artery. Further upward, it occupies medial surface of thyroid gland either medial or lateral to ligament of Berry. Nerve then passes deep to lower border of inferior constrictor and enters larynx behind cricothyroid joint
Branches	• Cardiac branches form deep cardiac plexus • Communicating branch joins with inferior cervical ganglion of sympathetic trunk • Braches to trachea and esophagus supply muscles, glands and mucosa • A motor twig to inferior constrictor muscle • Articular branches to cricothyroid and cricoarythenoid joints • Muscular branches to all intrinsic muscles of larynx except cricothyroid • Sensory branches to mucus membrane of larynx below the vocal folds	
Applied anatomy	• Recurrent laryngeal nerves may be injured in thryoid surgery or compressed by a growing tumor, aortic aneurysm or from any other causes • Right recurrent laryngeal nerve is more susceptible to damage during thyroid surgery due to its relatively medial location • If damage is unilateral, patient may present with voice changes including hoarseness • Bilateral nerve damage can result in breathing difficulties and aphonia	

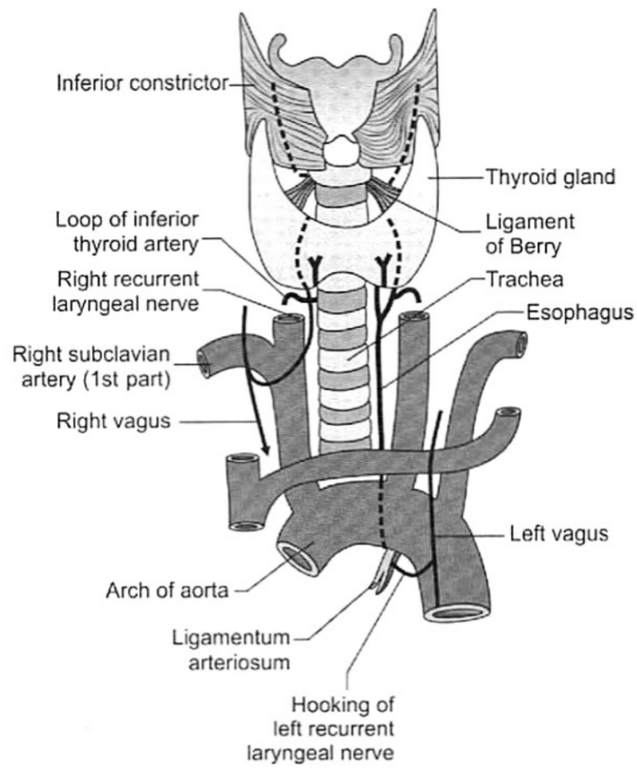

Figure 20: Recurrent laryngeal nerve—course

22. Bilateral adductor paralysis.

- Bilateral adductor paralysis is a functional disorder of speech seen as manifestation of hysteria characterized by sudden loss of voice in a normal healthy person.

Seen in	*Precipitating factor*
• Emotionally sensitive personality	• Emotional crisis

Clinical Features

- Seen in age group of 15–30 years
- Usually affects young females.

Symptoms	*Signs*
• History of emotional disturbance • Sudden loss of voice or voice may be reduced to whisper • No hoarseness • Pain in throat • Ability to whisper, cough or cry retained	• Vocal cords in abducted position and fail to adduct on phonation • Adduction of vocal cords seen on coughing • Anxious or depressed appearance of patient

Differential Diagnosis

Cerebral concussion	*Aphasia*
• Similar features • Rapid recovery	• Features of other neurological involvement

Treatment

Reassurance	*Persuasion*	*Speech therapy*	*Shock therapy*	*Psychotherapy*
• Reassurance to patient about restoration of laryngeal function	• Trying to restore voice by persuading patient to cough and utilize coughing to pronounce words like "Aa" and "Ba"	• Very useful	• Faradic stimulation of larynx or intravenous injection of calcium gluconate may be tried	• Required in stubborn cases

Prognosis

- Good but recurrences are common.

CHAPTER 61: BENIGN TUMORS OF LARYNX

Long Essay

1. Discuss the etiopathology, clinical features, management and complications of juvenile laryngeal papilloma.	15	J15(RS3)

Short Essays

1. Singer's nodule (vocal nodule).	325	J16(RS3), J04, J07, D08, D10, D13, J03(OS), J05(OS), D06(OS), D09(OS)
2. Vocal polyp (etiopathology and management).	43	J06, D03(OS)
3. Give an account of laryngocele.	350	D01, J05, J07, J12
4. Papillomas of larynx.	14	D07(RS2)
5. Juvenile laryngeal papillomatosis.	15	D17(RS3), D13
6. Discuss in brief multiple papillomas of larynx.	14	J08, J12(OS)
7. Recurrent laryngeal papilloma.	15	D03(OS)

Short Answers

1. Premalignant lesions of larynx.	286	J14(RS3)
2. Vocal nodule (Singer's nodule/laryngeal nodules)—management.	325	J14(RS3), D14(RS3), D17(RS3), J01, D01, D03, J08, D12, J13, D15, J17, J00(OS), J02(OS), J11(OS)
3. Vocal cord polyps.	43	J08(RS2), J11(RS2), D12(RS3), D16(RS3), J10
4. Laryngocele.	350	D17(RS3)
5. Laryngeal papilloma.	14	J15(RS3)

CHAPTER 62: CANCER LARYNX

Long Essays

1. Describe the etiology, symptoms, signs, investigations and treatment of carcinoma larynx.	158	D10(RS2)
2. How do you manage a stage III carcinoma larynx?	163	D07(RS2)

Short Essays

1. Pharyngocutaneous fistula.	38	J08(RS2)
2. Glottic cancers have high cure rate. Give reasons.	366	D00, J03, D04
3. TNM classification of carcinoma of glottis.	162	J15
4. Carcinoma of the vocal cord.	159	D99(OS)
5. Mention signs and symptoms of carcinoma glottis. How do you do staging of the same?	160	J13(OS)
6. Investigations and treatment of glottic cancer.	161	J04
7. Treatment of carcinoma larynx (T1 lesion).	163	J00(OS)
8. Speech rehabilitation following laryngectomy.	378	D05

Short Answers

1. TNM classification of carcinoma larynx.	162	D07
2. T1 glottic malignancy.	162	D03
3. Esophageal voice.	378	D00, D02, D04, J05

11. Papillomas of larynx.

- Papillomas are fronds of connective tissue covered by well-differentiated squamous epithelial covering with no invasion of stroma or submucosal tissues
- They are most neoplasm of larynx.

Types

a. Juvenile type
b. Adult onset type

	Juvenile type	*Adult onset type*
	• Recurrent laryngeal papilloma is squamous papilloma of larynx occurring in infants and young children • So called because of its aggressive behavior and tendency to recur even after surgical removal • Also called juvenile papilloma	• Also called solitary laryngeal papilloma
Etiology	*Causative organism* • Human papillomavirus—type 6 and 11 *Source of infection* • Infected mothers genitals during delivery	• Human papillomavirus
Pathology	*Gross appearance* • Glistening white warty irregular mass *Microscopic examination* • Finger like projection of epithelial tumor cells with central fibrovascular core	—
Clinical features	• Commonly affects infants and young children	• Common in males aged between 30–50 years
Symptoms	• Hoarseness • Difficulty in crying • Stridor	• Hoarseness of voice • Dyspnea, stridor or intermittent chocking (in case of large papilloma)
Signs	• Glistening white irregular growths on true and false cords and epiglottis • Multiple • May be sessile or pedunculated • Friable and bleeds easily	• Single, small, white to pinkish red, glistening mulberry like polypoid mass • Bleeds on touching • Arises from free edge of anterior half of vocal cord or anterior commisure • May be sessile or pedunculated
Treatment		
a. Conservative	• Interferon therapy (to prevent recurrence after surgical removal)	
b. Operative	• Endoscopic removal (using cup forceps, cryotherapy, CO_2 laser, microelectrocautery)	• Excision through microlaryngosurgery • Excision using KTP-532 or CO_2 laser
Prognosis	• Recurrence quite common even after surgical removal • Disappear spontaneously after puberty	• Premalignant condition but less aggressive • No recurrence after excision



Figure 12: Juvenile laryngeal papillomas

9. Singer's nodules.

- Singer's nodules are solid non-neoplastic lesions of vocal cords
- Also called laryngeal nodules or vocal nodules or screamer's nodules

Etiopathogenesis

Etiology	*Predisposing factors*	*Pathogenesis*
• Vocal trauma (speaking in unnatural low tones for prolonged periods or at high intensities)	• Chronic cough • Gastroesophageal disorder	Vocal cord abuse/misuse ⇓ Excessive vibration at junction of anterior 1/3rd and posterior 2/3rd of vocal cord ⇓ Edema and hemorrhage in submucosal space ⇓ Hyalinization and fibrosis ⇓ Hyperplasia of overlying epithelium ⇓ Vocal nodule

Pathology

Gross appearance	*Microscopic examination*
• Soft firm reddish nodules	• Nodules covered with normal squamous epithelium • Underlying edematous stroma • Increased vascularity, dilated blood vessels and hemorrhage • Keratosis, acanthosis and parakeratosis of surface epithelium in chronic cases

Clinical Features

- Usually occurs after puberty
- Mostly affects females
- Seen commonly in teachers, actors, hawkers or singers and assertive and talkative individuals

Symptoms	*Signs*
• Hoarseness of voice (due to incomplete approximation of cords) • Vocal fatigue at end of day • Neck pain on prolonged phonation	• Symmetrical bilateral swellings at junction of anterior 1/3rd with posterior 2/3rd (area of maximum vibration) • Vary from size of pin head to half a pea (rarely >1-5 mm) • Soft reddish edematous initially but later becomes grayish or white • May be small or may be large and polypoidal • May remain firm or may become soft or cystic

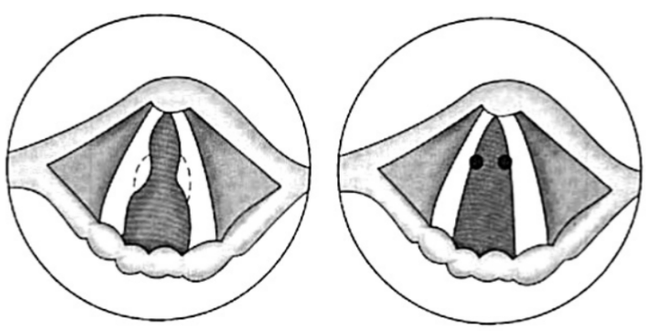

Early stage of vocal nodules Vocal nodules

Figure 3: Singer's nodules

Treatment

Conservative	*Operative*
• Voice rest for several weeks • Steroid inhalers (fluticasone propionate) in early cases • Speech therapy in early cases • Reeducation in voice production to prevent recurrence	• Excision of nodule by microlaryngoscopy for large nodules or chronic cases

15. Premalignant lesions of larynx.

- Precancerous lesions are those conditions which are not histologically malignant, but for which there is satisfactory proof that cancer occurs in them with higher incidence than corresponding normal tissues.

Examples	Predisposing factors
• Hyperkeratosis • Leukoplakia • Papilloma of larynx	• Chronic laryngeal irritation • Chronic laryngitis • Radiation burns

Pathology

- Hyperkeratosis is a thickening of superficial layers of the epithelium. The area may appear as having warty or grayish papillomatous appearance. Histologically, there is thickening of the stratum corneum with little or no inflammatory reaction in the underlying tissues
- Leukoplakia appears as a white patch usually on the cords and may look like a small prominent patch or a nodular plaque
- Solitary papilloma appears as pink warty growth of varying size in the anterior commissure arising from edge of the vocal cord in the anterior part and may be pedunculated
- Cellular atypia is evident

Pathogenesis

Hyperkeratosis
↓
Leukoplakia
↓
Carcinoma in situ
↓
Superficial invasive carcinoma
↓
Invasive carcinoma

Clinical Features

- Hoarseness of voice
- Involves upper surface of either one or both vocal cords but does not affect mobility of cord
- Lesions may be single or multiple.

Treatment	Prevention
• Microlaryngoscopy stripping of vocal cords	• Smoking cessation • Reduced alcohol drinking • Toxin free work environment • Healthy diet

---

22. Vocal cord polyps.

- Vocal polyps are most common benign lesions of larynx.

Etiopathogenesis

Etiology	Predisposing factors	Pathogenesis
• Vocal abuse or misuse	• Allergy • Smoking • Upper respiratory tract infection	Sudden shouting ⇓ Hemorrhage in vocal cord ⇓ Submucoal edema ⇓ Vocal polyp



Figure 12: Vocal polyp

Pathology

Gross appearance	Microscopic examination
• Soft, smooth, pedunculated swelling • May be bright reddish purple to pale translucent	• Relatively acellular scanty stroma distended with mucoid exudates • Fibrosis and fibrinoid and hyaline degeneration in stroma as lesion matures

Clinical Features

- Mostly affects males in age group of 30–50 years.

Symptoms	Signs
• Hoarseness of voice • Double voice (diplophonia) due to different vibratory frequencies of two vocal cords • Sticky sensation in throat • Dyspnea, stridor or intermittent chocking (in case of large polyp)	• Unilateral soft, smooth, pedunculated or sessile swelling • Arises from junction of anterior 1/3rd and posterior 2/3rd of vocal cord • May be bright reddish purple to pale translucent • May flop up and down glottis during respiration or phonation

Treatment

Conservative	Operative
• Speech therapy	• Excision by microlaryngosurgery

16. Laryngocele.

- Laryngocele is an air filled cystic swelling of larynx due to dilatation of saccule.

Etiology

- Congenital
- Acquired
  - Raised intraglottic air pressure
  - Chronic cough, asthma

Types

a. Internal	Confined within larynx producing distension under vestibular bands and aryepiglottic folds
b. External	Distended saccule herniates through thyroid membrane and presents a compressible swelling in region of thyroid cartilage
c. Combined or mixed	Both internal and external components

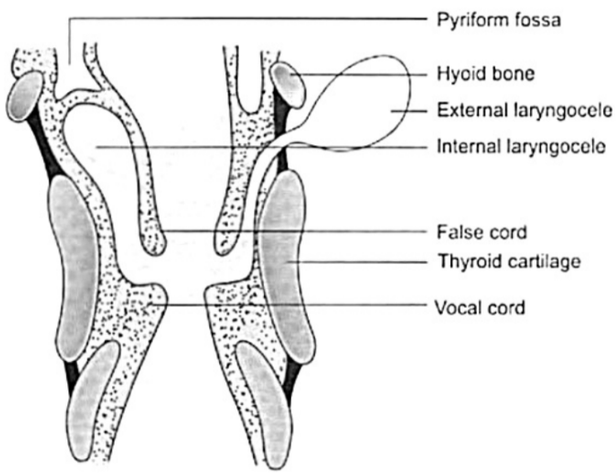

Figure 3: Laryngocele – Types

Clinical Features

- Seen in trumpet players, glass blowers or weight lifters
- Common in males

Symptoms

- Asymptomatic
- Hoarseness of voice
- Cough
- Dyspnea (due to pressure changes if large)

Signs

- Reducible swelling in neck which increases in size on coughing or performing Valsalva (external type)
- Gurgling and hissing sound in throat on external compression of neck swelling (Bryce's sign)



Figure 4: Internal laryngocele

Investigations

a. Radiography
  - X-ray AP and lateral view of neck with Valsalva reveals air filled sac becoming prominent with Valsalva
  - CT helps to find extent of lesion

b. Direct laryngoscopy
  - To rule out malignancy

Treatment

Operative

- Marsupialisation by laryngoscopy for internal laryngocele
- Surgical excision through transcervical incision

2. Describe the etiology, symptoms, signs, investigations and treatment of carcinoma larynx.

- Malignant laryngeal carcinoma are quite common in India.

Etiology ("*TARGET*")

a. Tobacco smoking	• Carcinogens like benzopyrene and other hydrocarbons in tobacco
b. Alcohol	• Acts synergistically with smoking increasing risk by 15 fold
c. Radiation	• Induction of carcinoma during radiation to neck for benign lesion or laryngeal papilloma
d. Genetic	• Familial tendency exhibited by laryngeal carcinoma
e. Environmental	• Occupation exposure to asbestos, mustard gas and other chemical or petroleum products
f. Tumor	• Solitary papilloma, leukoplakia, erythroplakia may turn malignant

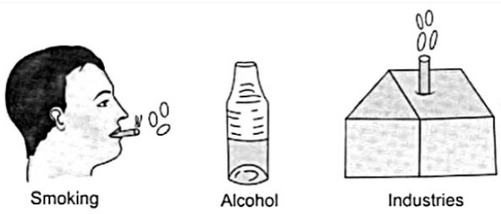

Figure 7: Laryngeal carcinoma—etiology

Classification (AJCC Classification, 2002)

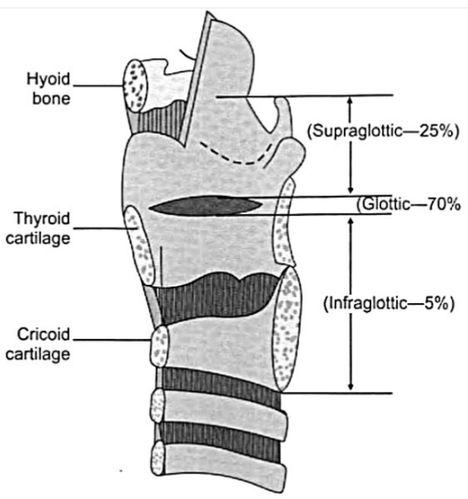

Figure 8: Laryngeal carcinoma—classification

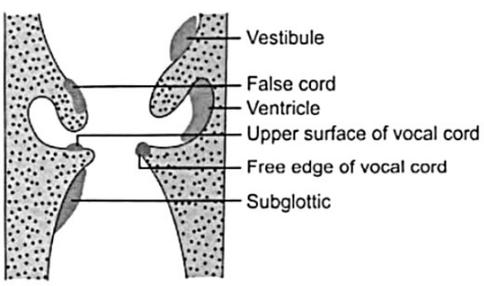

Figure 9: Laryngeal carcinoma—common sites

Supraglottic carcinoma (25%)	*Glottic carcinoma (most common – 70%)*	*Subglottic carcinoma (rare – 5%)*
• Suprahyoid epiglottis (both lingual and laryngeal surfaces) • Infrahyoid epiglottis • Ventricular bands (false cords) • Aryepiglottic folds (laryngeal aspect) • Arytenoids	• True vocal cords including anterior and posterior commisure	• Subglottis up to lower border of cricoids cartilage

Pathology

Gross appearance	*Microscopic examination*
• Proliferative (exophytic) usually well differentiated • Ulcerative (endophytic) usually poorly differentiated • Ulceroproliferative	• Most of lesions are squamous cell carcinoma (90–95%) with various grades of differentiation from well differentiated cordal lesions to anaplastic supraglottic lesions • Rest (5–10%) include verrucous carcinoma, spindle cell carcinoma, malignant salivary gland tumors and sarcomas

Spread

	Supraglottic cancer	*Glottic cancer*	*Subglottic cancer*
Direct spread	Adjoining areas like vallecula, base of tongue and pyriform fossa or extend into pre-epiglottic space and penetrate thyroid cartilage	Anterior commisure and then to opposite cord (anteriorly), vocal process and arytenoids region (posteriorly), ventricle and false cord (superiorly) and subglottic region (inferiorly)	Around anterior wall to opposite side or trachea and later to vocal cords, cricothryoid membrane, thyroid gland and ribbon muscles of neck
Lymphatic spread	Upper and middle jugular nodes	Does not occur (due to absence of lymphatics in cord) but may occurs if lesion spread beyond membranous cord	Prelaryngeal, pretracheal, paratracheal and lower jugular nodes

Clinical Features

- Seen mostly in adults above 40 years
- Males are 10 times more prone than females.

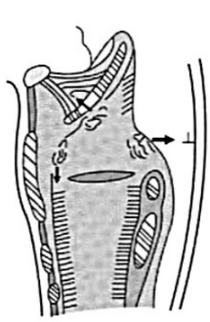

Spread of supraglottic cancer
1. From marginal region into pyriform sinus/postcricoid region
2. Into pre-epiglottic space
3. Inferiorly into subglottic space

Figure 10: Laryngeal carcinoma—spread

Symptoms

Supraglottic carcinoma	*Glottic carcinoma*	*Subglottic carcinoma*
• Muffled voice initially becoming hoarse later at advanced stage	• Persistent hoarseness of voice (early sign)	• Cough
• Foreign body sensation in throat	• Cough due to aspiration	• Hemoptysis
• Dysphagia	• Stridor (due to increase in size of growth with accompanying edema)	• Stridor
• Throat pain	• Laryngeal obstruction (due fixation of cord)	• Laryngeal obstruction
• Referred pain in neck and ear		• Hoarseness of voice (late symptom)
• Lymph node mass in neck		
• Weight loss		
• Laryngeal obstruction		
• Halitosis		

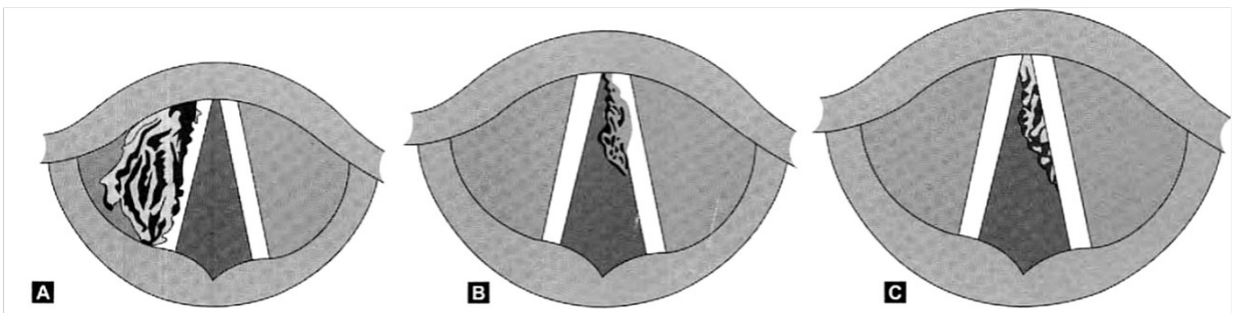

Figures 11A to C: (A) Supraglottic carcinoma; (B) Glottic carcinoma; (C) Subglottic carcinoma

Signs

a. Tumor mass
   - Proliferative growth for suprahyoid epiglottic lesion
   - Ulcerative lesion for infrahyoid epiglottic lesions
   - Raised nodule or ulcer or thickening at upper surface of vocal cords in anterior two third for glottic cancer
   - Granular tissue appearance of anterior commisure cancer
   - Raised submucosal nodules involving anterior half for subglottic cancer.

b. Vocal cord mobility
   - Impairment of vocal cord mobility due to deeper infiltration into thyroarytenoid muscle, cricoarytenoid muscle cricoarytenoid joint or invasion of recurrent laryngeal nerve.

c. Neck swelling
   - Midline neck swelling due spread of growth in anterior commisure and subglottic region through cricothyroi membrane.

Investigations

a. Radiography
   - X-ray (lateral view) neck to assess extent of lesion, involvement of pre-epiglottic space or destruction of thyroi cartilage
   - X-ray chest for co-existent lung disease, pulmonary metastasis or mediastinal nodes
   - Contrast laryngograms using radiopaque dye (dionosil) to outline surface extent of tumor
   - CT scan to determine extent of tumor, invasion of pre-epiglottic or paraepiglottic space, destruction of cartilag and lymph node involvement.

b. Diagnostic laryngoscopy
   - Direct laryngoscopy to visualize hidden areas of larynx and assess extent of disease
   - Microlaryngoscopy for small lesion of vocal cords and biopsy.

c. Supravital staining and biopsy
   - Staining of laryngeal lesions with toluidine blue and biopsy of stained areas.

TNM Staging

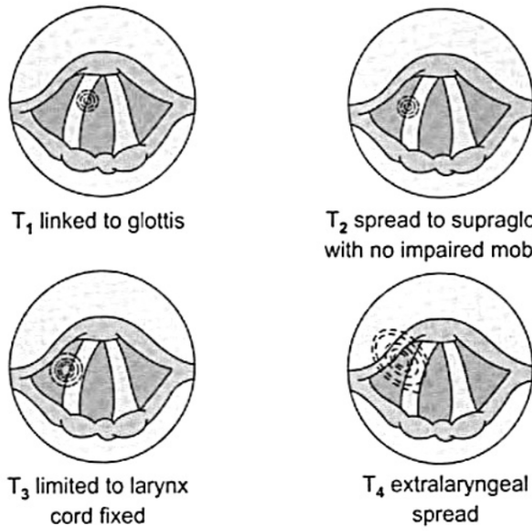

Figure 12: Laryngeal carcinoma—tumor staging

Stage	Tumor (T)			Nodal involvement (N)	Metastasis (M)
	Supraglottic	Glottic	Subglottic		
X	—	—	—	Cannot be assessed	Cannot be assessed
0	—	—	—	No metastasis	No distant metastasis
1a	Limited to one subsite with normal cord mobility	Limited on one cord with normal mobility	Limited to subglottis	Single ipsilateral node, 3 cm or less	Distant metastasis
1b		Involves both cords with normal mobility			
2a	Invasion of adjacent subsites without fixation	Invasion of supraglottis and/or subglottis with or without impaired cord mobility	Invasion of cords with or without impaired cord mobility	Single ipsilateral node, 3–6 cm	
2b				Multiple ipsilateral nodes, <6 cm	--
2c				Bilateral nodes, <6 cm	
3	Limited to larynx with cord fixation and/or invades either postcricoid area, pre-epiglottic tissue, paraepiglottic space and/or thyroid cartilage invasion	Limited to larynx with cord fixation and/or invades paraglottic space and/or minor thyroid	Limited to larynx with cord fixation	Nodes >6cm	--
4a	Invades through thyroid/cricoid cartilage and/or invades tissues beyond larynx (trachea, deep extrinsic tongue muscles, strap muscles, thyroid or eosophagus)			--	--
4b	Invades prevertebral space, mediastinal structures or encases carotid artery				

Grading

Grade	Tumor (T)	Nodal involvement (N)	Metastasis (M)
0	is	0	0
I	1	0	0
II	2	0	0
III	3	0	0

Contd...

Contd...

Grade	Tumor (T)	Nodal involvement (N)	Metastasis (M)
	1/2/3	1	0
IVA	4a	0	0
	4b	1	0
	1/2/3/4a	2	0
IVB	4b	0/1/2/3	0
	1/2/3/4	3	0
IVC	1/2/3/4	0/1/2/3	1

Treatment

Conservative

	Chemotherapy	Radiotherapy
Indications	• Palliative (alone) • Neoadjuvant (following radiotherapy or surgery) • Concomitant (simultaneously with radiotherapy)	• Curative (early stages) • Palliative (advanced stage) • Neoadjuvant (following surgery) • Anaplastic growths
Modalities		i. Curative – 6500 grays in 30 fractions over 5–6 weeks ii. Palliative – Lesser dosage

Operative

a. Laryngectomy

	Conservative	Total	Near total (partial)
Indications	• Early stages	• Lesions with cord fixation and beyond (T3 and T4) • Invasion of thyroid or cricoids cartilage • Bilateral arytenoid cartilage involvement • Lesions of posterior commisure • Failure of radiotherapy or conservative surgery • Transglottic cancer	
Contraindications		• Distant metastasis	
Procedure	• Excision of vocal cords after splitting larynx (cordectomy via laryngofissure)	• Involves excision of entire larynx including hyoid bone, pre-epiglottic space, strap muscles and 1 or more tracheal rings followed by pharyngeal wall repair and suturing of lower tracheal stump to skin for breathing • Partial pharyngectomy may be done if paraglottic space involved	• Larygectomy with leaving behind one functioning arytenoids and healthy subglottic mucosa which is used to reconstruct dynamic shunt connecting trachea to produce aspiration free voice • Excision of vocal cords and anterior commisure region (partial frontal laryngectomy)

b. Endoscopic laser excision
   - In early stages using CO_2 laser

c. Neck dissection (Modified/functional/selective)
   - To tackle lymph node and lymph bearing structures.

Treatment of Choice

Stage I and II (organ preservation techniques)	Stage III and IV (combined modality)
• Radiotherapy (treatment of choice) • Excision by laryngofissure technique • Conservative laryngectomy • Laser excision	• Total laryngectomy with neck dissection followed by radical radiotherapy (treatment of choice) • Radical radiotherapy followed by surgery for salvage

12. Pharyngocutaneous fistula.

- Pharygnocutenous fistula is serious and relatively common complication of head and neck surgery.

Etiology

Etiology	*Predisposing factors*
• Postoperative complication of – Total laryngectomy – Resection of oropharyngeal carcinoma • Penetrating neck injury	• Poor nutritional status • Prior irradiation • Poor surgical technique • Factors impairing wound healing like diabetes, preoperative hypoalbuminemia, chronic pulmonary diseases and chronic hepatopathy

Clinical features

- Usually seen 1–6 weeks after surgery.

Symptoms	*Signs*
• H/O operation in neck • Pain in lower neck • Associated with fever • Discharge of saliva and purulent material from incision	• Erythema and tenderness in lower neck incision or skin flap (initially) • Sloughing of neck skin exposing neural and vascular structures in neck (after few days)

Investigations

Methylene blue swallowing test	*Blood investigations*
• Confirms communication from skin to pharynx	• Leukocytosis

Prevention

- Gentle atraumatic handling of the soft tissues
- Achieving a watertight anastomosis
- Ensuring complete hemostasis
- Using closed suction drains to eliminate dead space.

Treatment

	Conservative	*Operative*
Indications	• Small fistulae	• Massive fistulae • Chronic, nonhealing fistulae
Techniques	i. Local wound care (antiseptic dressing, minimal debridement and antibiotics) ii. Parenteral feeding or nasogastric or gastrostomy tube feeding, with patient nil by mouth	i. Debridement and local closure ii. Regional tissue transfer (mucocutenous pedical flap) iii. Free tissue transfer

CHAPTER 63: VOICE AND SPEECH DISORDERS

Short Essays

1. Discuss the management of an adult patient presenting with hoarseness of voice.	8	J17(RS3)
2. 'Hoarse voice'—causes (in 50 years old male).	7	D07(RS2), D13
3. Functional aphonia.	151	D05, D11
4. Puberphonia.	134	D07(OS)
5. Rhinolalia.	72	J10

Short Answers

1. Enumerate causes of hoarseness in 50 years old female.	7	J10
2. Sudden aphonia.	151	D05(OS)
3. Puberphonia.	134	D09(RS2), J11, J15, D99(OS), J02(OS), D03(OS)
4. Rhinolalia.	72	D08(RS2)
5. Rhinolalia aperta (causes).	72	D01, J02, J13(OS)
6. Rhinolalia clausa.	72	J03, J16, J05(OS)

CHAPTER 64: TRACHEOSTOMY AND OTHER PROCEDURES FOR AIRWAY MANAGEMENT

Long Essay

1. Tracheostomy—define, indications, surgical procedure, postoperative care and complications.	9	J05(OS), D06(OS), J07(OS), J16(OS)

Short Essays

1. Advantages of tracheostomy over endotracheal intubation.	12	D06
2. Tracheostomy—types, indications (nonobstructive), procedure and complications.	9	D07(RS2), D08(RS2), J11(RS2), D12(RS3), J15(RS3), D16(RS3), J17(RS3), J04, D04, J08, J10, D14, J17, D00(OS), D07(OS), D12(OS)
3. Postoperative management after tracheostomy.	11	J03(OS)
4. What is emergency tracheostomy? Name the indications for it.	9	D02

Short Answers

1. Indications for tracheostomy.	9	D10(RS2), J12
2. Nonobstructive indication for tracheostomy.	9	D15
3. Decannulation of tracheostomy.	12	D11
4. Causes of decanulation problem.	12	D03
5. Complications of tracheostomy.	12	D05, J08, J16
6. Cricothyrotomy.	369	D01(OS)

CHAPTER 65: FOREIGN BODIES IN AIR PASSAGE

Short Essay

1. Foreign body in bronchus.	184	J11(RS2), D16(RS3), J13, D16

5. What are the causes of 'hoarse voice'?

- Hoarse voice (hoarseness) is rough and unpleasant voice resulting from variations of periodicity and/or intensity of consecutive sound waves.

Etiology

a. Inflammations

Acute	*Chronic*
• Acute laryngitis (following cold, influenza, exanthematous fever) • Laryngotracheobronchitis • Diphtheria	• Tuberculosis • Syphilis • Scleroma • Fungal infections • Chronic laryngitis • Atrophic laryngitis

b. Tumors

Benign	*Malignant*	*Tumor like mass*
• Papilloma (solitary and multiple) • Hemangioma • Chondroma • Fibroma • Leukoplakia	• Carcinoma	• Vocal nodule • Vocal polyp • Angiofibroma • Amyloid tumor • Contact ulcer • Cysts • Laryngocele

c. Trauma
   - Misuse or overuse of voice
   - External injuries to larynx (strangulations, cut throat, etc.)
   - Submucosal hemorrhage
   - Inhalation of irritant fumes
   - Foreign bodies
   - Intubation.

d. Paralysis
   - Recurrent laryngeal nerve paralaysis
   - Superior laryngeal nerve paralysis.

e. Fixation of cords
   - Arthritis or fixation of cricoarytenoid joints.

f. Congenital
   - Laryngeal web
   - Laryngeal cyst
   - Laryngocele.

g. Miscellaneous
   - Dysphonia plica ventricularis
   - Myxedema
   - Gout.

h. Functional
   - Hysterical aphonia.

Investigations

Indirect laryngoscopy	*Direct laryngoscopy or flexible fiberoptic laryngoscopy*	*Microlaryngoscopy*	*Bronchoscopy and esophagoscopy*	*Radiology*
• Reveals many local laryngeal causes	• Confirms any local laryngeal causes and helps to obtain laryngeal swab for smear and culture	• Helps in precise diagnosis and obtain biopsy of lesion or assessment mobility of cricoarytenoid joints	• To exclude malignancy in paralytic lesions of cord	• X-ray (plain and contrast) and CT scans to confirm diagnosis

Treatment

Supportive	*Conservative*	*Operative*	*Specific*
• Voice rest • Steam inhalation (of tincture benzoin, menthol, camphor, etc.) to reduce congestion • Speech therapy (to teach patient to speak in relaxed manner without straining vocal cords)	a. Antibiotics – In case of inflammatory conditions b. Anti-inflammatory drugs – To reduce congestion and edema	• Phonosurgery	• Treatment of underlying cause

19. Puberphonia.

- Persistence of childhood high-pitched voice in males even after puberty is called puberphonia.

Seen in	*Pathophysiology*
• Emotionally immature or psychologically disturbed boys	• Boys with feeling of insecurity and excessive fixation to their mothers shun to assume male responsibilities

Features

- Childlike high-pitched voice
- Normal physical and sexual development.

Treatment

- Gutzmann's pressure test
  - Helps produce low-pitch voice by pressing thyroid prominence backward and downward to relax overstretched cords.

19. Rhinolalia.

- Change in tonal quality of voice due to nasal or nasopharyngeal problems is called rhinolalia.

Types

a. Rhinolalia clausa (hyponasality).
b. Rhinolalia aperta (hypernasality).

	Rhinolalia clausa	*Rhinolalia aperta*
Words affected	Lack of nasal resonance for words which resonate in nasal cavity (m, n, ng)	Nasal resonance of words which have little nasal resonance
Pathogenesis	Because air does not pass through nose due to blockage of nose or nasopharynx	Because of failure of nasopharynx to cut off from oropharynx or abnormal communication between oral and nasal cavities
Etiology	• Common cold • Nasal allergy • Nasal polypi • Nasal growth • Adenoids • Nasopharyngeal mass • Familial speech pattern • Habitual	• Valopharyngeal insufficiency • Congenitally short soft palate • Submucous palate • Large nasophayrnx • Cleft palate • Paralysis of soft palate • Post adenoidectomy • Post surgery for sleep apnoea • Oronasal fistula • Familial speech pattern • Habitual
Features	• Flat dull voice (potato in mouth voice)	• Nasal twang to voice • Nasal regurgitation
Treatment	Treatment of underlying cause	*Conservative* • Speech therapy in mild cases *Operative* Indications • Major defect • Failure of conservative therapy

	Rhinolalia clausa	*Rhinolalia aperta*
		Techniques • Repair of cleft palate using VY plasty to push back palate • Implantation of materials (silastic, Teflon, cartilage) in posterior pharyngeal wall • Pharyngoplasty by pharyngeal flaps to decrease size of nasopharyngeal sphincter

9. Tracheostomy.

- Tracheostomy is a surgical opening in anterior tracheal wall which is converted into stoma on skin surface by inserting a tube.

Types

Emergency	*Elective or routine (tranquil)*		*Permanent*
Done urgently to establish airway in presence of complete or almost complete airway obstruction	Temporary tracheostomy done after thorough planning with availability of all necessary surgical facilities and instruments		Done in cases of bilateral abductor paralysis or laryngeal stenosis
	Therapeutic	*Prophylactic*	
	To relieve respiratory obstruction, remove tracheobronchial secretions or give assisted ventilation	To guard against anticipated respiratory obstruction or aspiration of blood or pharyngeal secretions	

Location

	High tracheostomy	*Mid tracheostomy*	*Low tracheostomy*
Location	At 1st tracheal ring, above level of thyroid isthmus	At level of 2nd or 3rd tracheal ring	Below level of thyroid isthmus
Indications	Carcinoma of larynx when laryngectomy is anticipated	Most preferred site for routine tracheostomy	Laryngeal papillomatosis to avoid implantation Enlarged thyroid isthmus
Disadvantages	Damage to 1st tracheal ring and causes perichondritis of cricoid cartilage and subglottic stenosis		Chances of injury to several large vessels lying close to trachea and impingement of tracheostomy tube on suprasternal notch

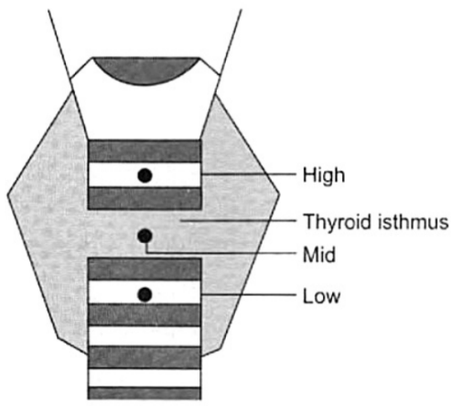

Figure 6: Tracheostomy—location (types)

Indications

Obstructive			*Non-obstructive (All 'A's)*
Respiratory obstruction	*Retained secretion*	*Respiratory insufficiency*	
a. Infections – *Acute laryngotracheobronchitis#* – *Acute epiglottitis#* – *Diphtheria#* – Ludwig's angina – Peritonsillar abscess – Retropharyngeal abscess – Parapharyngeal abscess – Tongue abscess	a. Inability to cough – Coma of any cause (head injuries, cerebrovascular accidents, narcotic overdose) – Paralysis of respiratory muscles (spinal injuries, polio, GB syndrome, myasthenia gravis) – Spasm of respiratory muscles (tetanus, eclampsia, strychnine poisoning)	• Chronic lung conditions (emphysema, chronic bronchitis, bronchiectasis, atelectasis) • Respiratory paralysis • Severe chest injuries, flail chest	• Assisted ventilation • Aspiration • Anesthesia • Alaryngeal • Atelectasis
b. Trauma – *External injury to larynx and trachea#* – *Cut throat injury to larynx#* – *Strangulation and crush injury to larynx#* – *Trauma due to endoscopies*#* – Fracture of mandible – Maxillofacial injuries	b. Painful cough – Chest injuries – Multiple rib fractures – Pneumonia		
c. Neoplasms – Benign and malignant neoplasms of URT, tongue and thyroid	c. Aspiration of pharyngeal secretions – Bulbar polio – Polyneuritis – Bilateral laryngeal paralysis		
d. Foreign body – Laryngeal foreign body			
e. *Laryngeal edema#* – Due to steam, irritant fumes, allergy, radiation			
f. Neurological – *Bilateral abductor paralysis**			
g. Congenital anomalies – *Laryngeal web and cysts** – *Tracheoesphageal fistula** – *Bilateral choanal atresia** – *Glottis web** – *Subglottic stenosis or hemangioma**			

Note: Indications in infants*—Underlined; *Indications in children#—Italicized*

Contraindications

- Bleeding disorders
- General debility
- Diabetes and hypertension.

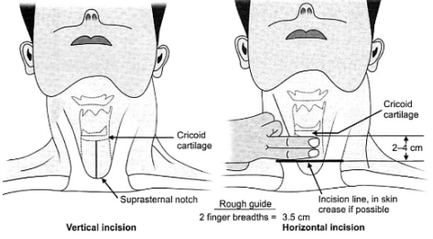

Figure 8: Tracheostomy—incisions

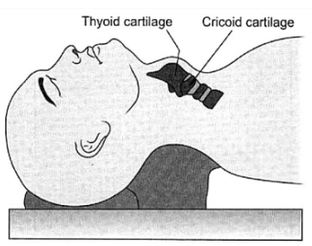

Figure 7: Tracheostomy—position

Procedure

Position

- Supine with extended neck (by placing a pillow under shoulders) with surgeon standing on right of patient.

Anesthesia

- Not required (in emergency and unconscious patients)
- Local anesthesia with 1–2% lignocaine with epinephrine (elective tracheostomy).

Incision

- A vertical incision in midline of neck, extending from cricoids cartilage to just above sternal notch—in emergen and for beginners
- 5 cm long transverse incision, 2 fingers breadth above sternal notch (in elective tracheostomy for cosmetically bett scar)—for elective surgeries

Steps

- Make desired incision
- Dissect tissue in midline
- Separate and retract strap muscles laterally using C-shaped or right angled retractors
- Incise pretracheal fascia below isthmus and expose trachea
- Thyroid isthmus is displaced upward (for low tracheostomy) or divided between clamps and suture ligated (for mid tracheostomy)
- Achieve complete hemostasis to prevent tricking of blood into trachea
- Inject few drops of 4% lignocaine into trachea (to suppress cough while incising trachea)
- Fix trachea with hook and opened with a vertical incision in region of 3rd-4th or 2nd or 3rd ring
- Convert vertical tracheal opening into a circular opening
- Insert tracheostomy tube of appropriate size and secure it by tapes
- Do not suture skin incision or pack it tightly (to prevent development of subcutaneous emphysema)
- Place gauze dressing between skin and flange of tube around stoma.

Postoperative Care

Constant supervision	*Suction*	*Prevention of crusting and tracheitis*	*Tracheostomy tube care*
• For bleeding, displacement of tube, blocking of tube and removal of secretions • Temperature, pulse and BP recorded 4 hourly	• Every half hourly to hourly depending upon amount of secretion • Done by applying suction to catheter only when withdrawing it	• Proper humidification by use of humidifier, steam tent, ultrasonic nebulizer or keeping a boiling kettle in room • Loosening crusts using few drops of normal or hypotonic saline or Ringer's lactate every 2–3 hours along with acetylcysteine to liquefy tenacious secretions	• Inner cannula should be removed and cleaned, as and when indicated for first 3days • Outer cannula should not be removed for 3–4 days unless indicated (for allowing track to be formed) after which it should be removed and cleaned every day

Decannulation

- Decannulation is removal of tracheal tube which should be done as early as possible.

Procedure	*Decannulation problems*	*Causes of decannulation problems*
• Plug tracheostomy tube and observe whether patient can tolerate it for 24 hours • If patient can tolerate it, then tube can be safely removed (in operation theatre if feasible) • Wound is taped and patient is closely observed • Wound healing takes few days to week	(seen commonly in infants and children) • Respiratory distress • Tachycardia • Cyanosis	• Persistence of underlying conditions • Obstructing granulations around stoma or below it • Tracheal edema or subglottic stenosis • Incurving of tracheal wall at site of tracheostome • Tracheomalacia • In-coordination of laryngeal opening reflex • Inability to tolerate upper airway resistance • Psychological dependence on tracheostomy

Complications

Immediate (on operating table)	*Intermediate (few hours to days)*	*Late (due to prolonged use of tube for weeks and months)*
• Hemorrhage • Apnea (in patients with prolonged respiratory obstruction due to sudden washing out of CO_2) • Pneumothorax (due to injury to apical pleura) • Injury to recurrent laryngeal nerves • Aspiration of blood • Injury to esophagus (resulting in tracheoesphageal fistula) • Injury to high innominate artery (in children)	• Reactionary hemorrhage (within 48 hours) • Secondary bleeding (on 5th to 8th day due to infection) • Displacement of tube • Blocking of tube • Subcutaneous emphysema • Tracheitis and tracheobronchitis with crusting in trachea • Atelectasis • Lung abscess • Local wound infection and granulations	• Hemorrhage (due to erosion of major vessel) • Laryngeal stenosis (due to perichondritis of cricoid cartilage) • Tracheal stenosis (due to tracheal ulceration and infection) • Tracheomalacia (due to excision of large area of trachea) • Tracheoesophageal fistula (due to prolonged use of cuffed tube or erosion of trachea by tip of tube) • Decannulation problems (seen commonly in infants and children) • Persistent trachaocutaneous fistula • Tracheostomy scar or keloid • Corrosion of tracheostomy tube and aspiration of its fragments into tracheobronchial tree

Sequel	*Functions*	*Advantages (over prolonged endotracheal intubation)1*
• Loss of speech (because of bypassing of larynx) • Anosmia (because patient does not breath through nose)	• Alternative pathway for breathing • Improves alveolar ventilation (↓ dead space by 30–50% and reducing airflow resistance) • Protects airway against aspiration of pharyngeal secretions, blood, etc. • Permits removal of tracheobronchial secretions (in patients unable to cough) • Permits prolonged intermittent positive pressure respiration (more than 72 hours) • Permits administration of anesthesia, medications or humidification	• Reduces patient discomfort • Reduces need for sedation • Improves ability to maintain oral and bronchial hygiene • Reduces risk of glottic trauma • Reduces dead space and reduces work of breathing • Augments process of weaning from ventilatory support

9. Foreign body in bronchus.

- Small foreign bodies ingested accidently may lodge anywhere in bronchus after passing through vocal cords.

Etiology

Etiology	*Predisposing factors*
• Accidental • Intentional in psychiatric patients	a. Interference with deglutition reflex – Due to coughing, crying or tapping on back while swallowing may lead to inhalation of food into bronchi b. Altered sensorium – Inhalation of fluid, food is seen in unconscious, drunken and anesthetic people c. Neurological imbalance – Paralysis of pharynx or larynx d. Improper mastication – Hurried swallowing of improperly masticated food may lead to inhalation of food

Nature of Foreign Bodies

Nonirritating type	*Irritating type*
• Less irritant • Remain symptomless for long time • Cause granuloma-hemoptysis • For example, plastic, glass or metallic objects	• More toxic • Sets up a diffuse violent reaction leading to congestion and edema of tracheobronchial mucosa (vegetal bronchitis) • Cause airway obstruction by swelling up and later causing suppuration in lungs • For example, groundnut, seeds of fruits like chikoo, custard apple, grams

Clinical Features

- Common in children esp. below 4 years of age.

Stage of inhalation	*Latent stage*	*Stage of manifestations*
• Lasts for a short time • Characterized by choking, gagging and wheezing • Patient become cynosed • Death may occur in case of large foreign bodies • Foreign body may be coughed out or lodge in tracheobronchial tree	• Lasts for variable period depending upon size and nature of foreign body (shorter in larger and vegetable foreign bodies) • Disappearance of initial symptoms as respiratory mucosa adopts to foreign body	• Caused by obstruction to airway, inflammation or trauma induced by foreign body • Foreign bodies usually enter right bronchus because it is wider and more in line with tracheal lumen i. Wheeze - Caused by partial obstruction ii. Atelectasis - Due to total obstruction of lobar or segmental bronchus, thus preventing entry of air but only exit

Stage of inhalation	*Latent stage*	*Stage of manifestations*
		iii. Obstructive emphysema - Due to producing check valve obstruction allowing only entry of air but no exit iv. Acute laryngotracheobronchitis - Due to infection or chemical irritation usually caused by vegetable foreign bodies

Investigations

a. X-ray chest (PA and lateral view)	• May demonstrate radio-opaque foreign bodies • May be normal or show atelectasis, emphysema or mediastinal shift (if taken at end of inspiration and expiration)
b. CT scan	• May be useful
c. Fluroscopy	• During inspiration and expiration
d. Bronchogram	• To delineate radiolucent foreign bodies
e. Bronchoscopy	• Dual benefit of diagnostic and therapeutic procedure

Differential Diagnosis

- Acute laryngotracheobronchitis
- Pneumonia
- Bronchopneumonia
- Atelectasis.

Treatment

Conservative	*Operative*
a. Antibiotics – To prevent secondary infection b. Steroids – Started at earliest in full dose to prevent laryngeal edema following prolonged bronchoscopy	a. Bronchoscopy – Treatment of choice – Confirms diagnosis and aids removal of foreign body – Failure to perform bronchoscopy may be much more disastrous than risk involved in performing bronchosocpy (Jackson's dictum) b. Tracheostomy *Indications* – Laryngeal stridor – Laryngeal edema – To reduce dead space – For inserting large bronchoscope – Removal of large swollen foreign body (obstructing at vocal cords) – Tracheobronchial toilet for secretions c. Thoracotomy and bronchotomy – Indicated when foreign body cannot be removed by bronchoscopy d. Lobectomy or pneumonectomy – Indicated in old neglected foreign bodies causing severe damage to lobe of lung or entire lung

CHAPTER 66: THYROID GLAND AND ITS DISORDERS

Short Essay

1. Lingual thyroid.	34	J08(RS2)

Short Answer

1. Lingual thyroid.	34	J12(RS2), J13(RS3)

6. Lingual thyroid.

- Lingual thyroid is presence of ectopic thyroid tissue in base of tongue.

Etiopathogenesis

- Developmental anomaly in thyroid development
- Thyroid develops from thyroglossal diverticulum
- Lingual thyroid results due to congenital persistence of thyroid tissue in region of foramen cecum (in midline at junction of anterior 2/3rd and posterior 1/3rd of tongue).

Clinical Features

- Usually affects females.

Symptoms	*Signs*
i. Small size – Asymptomatic ii. Large (increases in size during period of stress like menarche, hemorrhage into it) – Gradually increasing foreign body sensation – Dysphagia – Hot potato speech	◆ Well demarcated smooth reddish swelling in midline of tongue

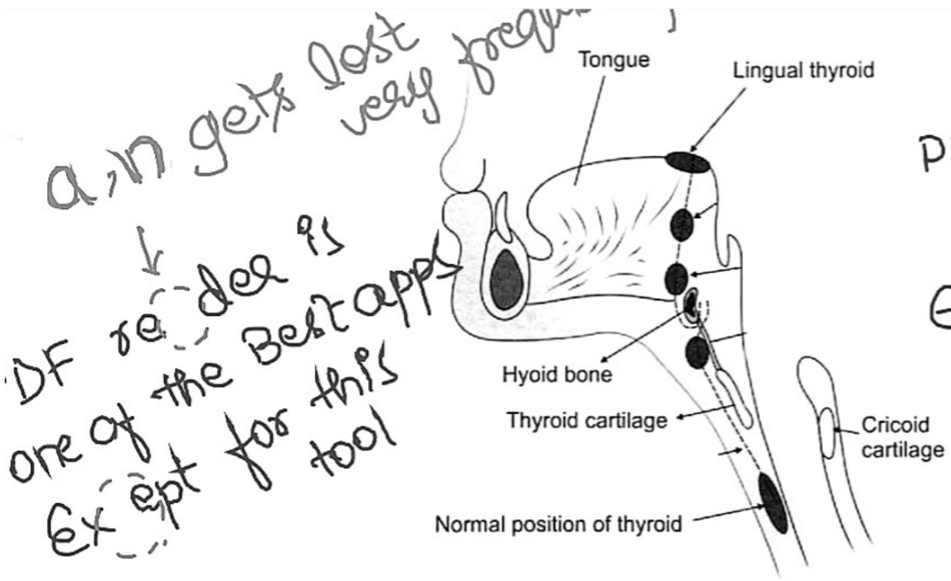

Figure 7: Lingual thyroid

Investigations

Thyroid function test	*Thyroid scan*
◆ T3, T4 and TSH assay	◆ Detects ectopic thyroid tissue

Treatment

Conservative	*Operative*
◆ No treatment if asymptomatic ◆ Thyroxine supplementation if TSH raised	◆ Excision by transoral or transcervical approach (in presence of other functioning thyroid tissue) ◆ Pedicled translocation in lateral cervical gutter or reimplantation in sternomastoid or rectus abdominus muscle (if only functioning thyroid tissue)

SECTION VII: DISEASES OF ESOPHAGUS

CHAPTER 67: ANATOMY AND PHYSIOLOGY OF ESOPHAGUS

Long Essay

1. Discuss the physiological basis and mechanism (phases) of deglutition.	44	D08(RS2), J14

Short Essay

1. Describe the mechanism of deglutination.	44	J01(OS)

Short Answer

1. Constrictions of esophagus.	314	D15(RS3)

CHAPTER 68: DISORDERS OF ESOPHAGUS

Short Essays

1. Esophageal perforation.	21	J16(OS)
2. Plummer-Vinson (Paterson Brown Kelly) syndrome.	292	D14(RS3), D05, J07, D13, J07(OS), D09(OS), J10(OS)
3. Globus hystericus.	233	D06
4. Achalasia cardia.	379	J07, D00(OS), D07(OS), J12(OS)

Short Answers

1. Esophageal perforations.	21	D07(RS2)
2. Plummer-Vinson (Patterson Kelly) syndrome.	292	J15(RS3), J08, J03(OS), J16(OS)
3. Globus pharynges (globus hystericus).	233	J12(RS2), J13(RS3), J11
4. Achalasia cardia.	379	D03(OS)

CHAPTER 69: DYSPHAGIA

Long Essay

1. How will you manage a case of 50 years old woman presenting with dysphagia.	173	D15

Short Essays

1. Dysphagia—causes/management.	173	D10(RS2), D17(RS3), J02, J15, J02(OS), D02(OS)
2. Dysphagia lusoria.	174	D11

Short Answer

1. Dysphagia lusoria.	174	J11(OS)

CHAPTER 70: FOREIGN BODIES IN FOOD PASSAGE

Short Essay

1. Clinical features and management of foreign bodies in esophagus.	380	J09

Short Answers

1. Foreign body in cricopharynx.	380	D10
2. Foreign body esophogus.	380	D01, J12(OS)
3. Management of ingested foreign body.	381	J06

1. Discuss the physiological basis and mechanism of deglutition.

- Deglutition or swallowing is a process by which chewed food is emptied from mouth into stomach
- It is initiated voluntarily but ends reflexly.

Stages

Oral stage	*Pharyngeal stage*	*Esophageal stage*
Voluntary stage pushing food from mouth into pharynx	Involuntary stage pushing food from pharynx into esophagus	Involuntary stage transporting food into stomach through series of peristaltic waves in esophagus

a. Oral stage or first stage
   - Voluntary stage where food enters from mouth into pharynx.

   Mechanism
   - Once bolus of food is formed, it is projected on to back of the tongue
   - Tongue is elevated and pressed against hard palate and moved backwards
   - Soft palate is elevated and bolus is propelled into pharynx.

b. Pharyngeal stage or second stage
   - Involuntary stage pushing bolus of food from pharynx into esophagus
   - Also called swallowing reflex
   - Receptors of this reflex are present in vicinity of anterior and posterior pillars of fauces and tonsils
   - Impulse is sent to swallowing center in medullary reticular formation via trigeminal and glossopharyngeal nerves
   - Vth, VIth, IX, X and XII nerves carry motor impulse from swallowing center
   - This reflex also inhibits respiration, sneezing, coughing and vomiting during this stage.

   Mechanism
   - Once bolus enters pharynx, it can enter 4 ways which are:

     • Back into mouth • Upward into nasopharynx • Forward into larynx • Downward into esophagus

   - Various movements are coordinated, so that bolus enters only into esophagus
   - Entry of bolus in other ways is prevented as follows:

Back into mouth prevented by	*Upward into nasopharynx prevented by*	*Forward into larynx prevented by*
• Position of tongue against roof of mouth • High intraoral pressure developed by movements of tongue	• Elevation of soft palate	• Approximation of vocal cords • Forward and upward movements of larynx • Backward movement of epiglottis to close larynx • Deglutition apnea which is temporary unrest of breathing occurring in this stage

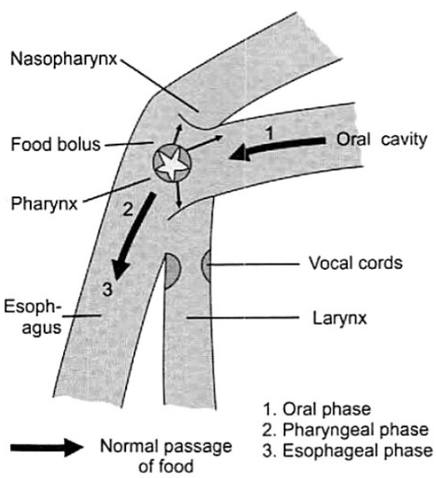

Figure 1: Phase of deglutition

   - Entry of bolus into the esophagus is favored by:
     - Closure of rest 3 outlets
     - Stretched opening of larynx by upward movement of larynx
     - Relaxation of the upper esophageal sphincter
     - Peristaltic movements of pharynx
     - Elevation of the larynx lifts the glottis away from the food passage
   - Above all movements occur simultaneously in a coordinated fashion to facilitate entry of bolus into esophagus in this 2nd stage of deglutition which lasts only for 1-2 seconds.

c. Esophageal stage or third stage
   - Involuntary stage where bolus of food is transported to stomach by a series of peristaltic waves in esophagus.

   Mechanism
   - Two types of peristaltic waves occurring in esophagus are primary and secondary peristaltic contractions.

Primary peristaltic contractions	*Secondary peristaltic contractions*
• These start when bolus reaches upper part of esophagus • These contractions pass downward and propel bolus towards stomach by developing a pressure	• Arise locally in esophagus due to distention of upper esophagus by bolus • Travel downward producing a positive pressure (similar to primary peristalsis) • Waves appear even in absence of primary peristaltic waves and push bolus into stomach

Significance

- Deglutition is first and an important process in gastrointestinal system helping food to move from mouth into stomach.

14. Constrictions of esophagus.

- Esophagus is a 25 cm long fibromuscular tube, extending from lower end of pharynx (C6) to cardiac end of stomach (T11)
- It runs vertically but inclines to left from its origin to thoracic inlet and again from T7 to esophageal opening in diaphragm
- During its course it shows 3 normal constrictions (4 according to Anatomy textbooks).

Constrictions of Esophagus

Location	Vertebral level	Distance from upper incisors
a. At pharyngoesophageal junction	C6	15 cm
b. At crossing of arch of aorta and left main bronchus	T4	25 cm
c. At crossing of left main bronchus	T5	27 cm
d. Where it pierces diaphragm	T10	40 cm

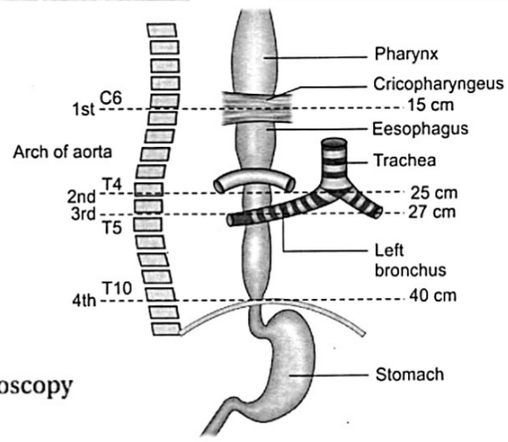

Figure 4: Constrictions of esophagus

Significance

- It is important to know the location (distance from upper incisors) for esophagoscopy
- Foreign bodies in esophagus usually are held up at these constrictions.

9. Plummer-Vinson syndrome.

- Syndrome characterized by gradually progressive dysphagia to solids with microcytic hypochromic anemia and chronic pharyngoesophagitis
- Also called Peterson-Brown-Kelly syndrome, sideropenic dysphagia.

Etiopathogenesis

Etiology	Pathology
• Iron deficiency anemia – May cause it or may result due it • Geography – Common in people of Scandinavian origin	• Thinning of mucosa of upper alimentary tract with disappearance of rete pegs • Degeneration of esophageal musculature • Submucosal fibrosis and atrophy of mucosa forming web at pharyngoesophageal junction

Clinical Features

- Predominantly affects females aged 40 years.

Symptoms	Signs
• Difficulty in swallowing (dsyphagia) for solids initially followed by liquids • Lump in throat • Painful oral ulcers	• Pallor (due to iron deficiency anemia) • Glottitis • Angular stomatitis • Koilnychia (spooning of nails) • Splenomegaly

Investigations

Blood investigations	Gastric analysis	Barium meal or swallow	Esophagoscopy
• Reveals iron deficiency anemia • ↓ iron levels • ↑ iron binding capacity	• Reveals achlorhydria	• Shows a web in postcricoid region or narrowing of hypopharynx	• Demonstrates web formation in hypopharynx and detects malignant transformation

Treatment

Conservative	Operative
• Correction of anemia with oral/parenteral iron and vitamin B_{12} and B_6	• Esophageal bougies to dilate webbed area • Endoscopic dilatation of postcricoid region

Complications

- Postcricoid carcinoma (10%)
- Carcinoma of tongue, buccal mucosa, pharynx, esophagus and stomach.

9. Causes of dysphagia.

- Dysphagia is difficulty in swallowing.

Etiology

Preesophageal (disturbance in oral or pharyngeal phase of deglutition)	*Esophageal causes (disturbance in esophageal phase of deglutition)*	*Functional*
A. Oral phase a. Disturbance in mastication - Trismus - Fracture of mandible - Tumors of upper or lower jaw - Disorders of TM joint b. Disturbance in lubrication - Xerostomia following radiotherapy - Milkulicz disease c. Disturbance in mobility of tongue - Paralysis of tongue - Painful ulcers - Tumors of tongue - Lingual abscess - Total glossectomy d. Defects of palate - Cleft palate - Oronasal fistula e. Lesions of buccal cavity and floor of mouth - Stomatitis - Ulcerative lesions - Ludwig's angina B. Pharyngeal phase a. Obstructive pharyngeal lesions - Tumors of tonsils, soft palate, base of tongue, supraglottic larynx - Obstructive hypertrophic tonsils b. Inflammatory conditions - Acute tonsillitis - Peritonsillar abscess - Retro- or parapharyngeal abscess - Acute epiglottitis - Laryngeal edema c. Spasmodic condition - Tetanus - Rabies d. Paralytic condition - Paralysis of soft palate due to diphtheria, bulbar palsy, cerebrovascular accidents	A. In lumen - Foreign body - Large bolus B. In wall a. Congenital - Tracheoesphageal fistula - Stricture b. Traumatic - Corrosive poisoning c. Inflammation - Hiatus hernia with lower esophagitis - After exanthemata d. Neoplasms - Leiomyoma - Carcinoma of esophagus e. Neurological - Paralytic - Spasm of cricopharynx and esophagus - Tetanus - Myasthenia gravis f. Miscellaneous - Plummer Vinson syndrome - Achalasia - Hypopharyngeal diverticulum C. Pressure on esophagus a. Cervical - Malignancy of thyroid gland - Malignancy of lymph node - Pharyngeal pouch - Cervical spondylosis (cervical osteophytes) b. Thoracic - Aneurysm of aorta - Mediastinal tumors - Lymphadenophaty in Hodgkin's disease - Tuberculosis - Cardiac enlargements - Pericardial effusion - Retrosternal goiter - Vascular rings by aberrant blood vessel (dysphagia lusoria) c. Abdominal - Hepatic enlargement	• Globus hystericus

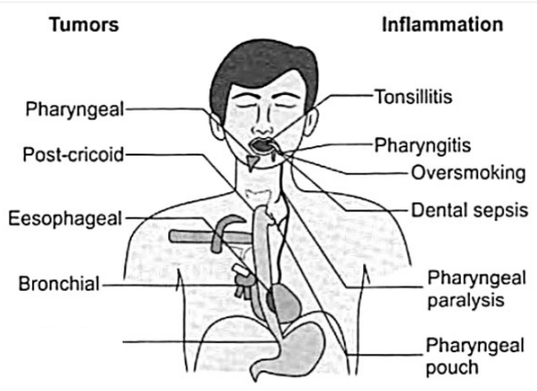

Figure 20: Dysphagia—causes

Clinical Features

- Any age may be affected depending upon underlying pathology:
  - Achalasia cardia—common in 3rd and 4th decade of life
  - Malignancy seen mostly in elderly above 40 years of age.
- Sexes may also be affected based on etiology:
  - Malignancy common in males
  - Plummer Vinson syndrome exclusively in females.

- History of previous conditions suggesting underlying condition present:
  - History of foreign body ingestion
  - History of corrosive poisoning
  - History neurological conditions like polio, diphtheria, etc.

Symptoms	Signs
• No symptoms at early cases • Acute dysphagia may be due to foreign bodies or acute esophagitis • Chronic dysphagia may present as acute dysphagia • Dysphagia to solids is presenting feature of strictures and malignancy • Dysphagia to liquids is characteristics of achalasia cardia	• Vary depending upon underlying etiology

Investigations

a. Radiography

i. X-ray chest	• To exclude cardiovascular, pulmonary and mediastinal diseases
ii. Lateral view of neck	• To exclude cervical osteophytes and soft tissue involvement of post-cricoid or retropharyngeal spac
iii. Barium swallow	• Ideal to diagnose malignancy, achalasia, strictures, diverticula, hiatus hernia or esophageal spasms
iv. CT scan	• Detects space occupying lesions

b. Manometric and pH studies
   - To detect motility disorders, gastroesophageal reflux diseases

c. Endoscopy
   - Esophagoscopy, laryngoscopy and bronchoscopy with biopsy

d. Others
   - Thyroid scan (for thyroid malignancy)
   - Cardiac catheterization (for vascular anomalies).

18. Globus hystericus.

- A psychosomatic disorder
- Also called globus pharyngeus.

Etiology

- Psychological
- Cancer phobia
- Hyperacidity.

Clinical Features

- Usually affects adults and mostly females.

Symptoms	Signs
• Lump in throat between meals rather than during a meal • No dysphagia to solids or liquids • Anxiety due to fear of throat cancer	• Normal pharynx, larynx and base of tongue

Investigations

Radiological	Oesophageal
• Barium swallow under fluoroscopy • X-ray neck	• Flexible esophagoscopy • Manometric studies

Differential Diagnosis

- Cricopharyngeal spams
- Pharyngeal pouch
- Gastroesophageal reflux disease
- Achalasia cardia
- Hiatus hernia
- Treatment
- Reassurance
- Tranquillisers to control symptoms
- Placebo treatment
- Psychiatric treatment if required.

15. Esophageal perforations.

- An emergency condition due to tear in esophageal wall.

Etiology	*Sites of perforation (types)*
• Ingestion of sharp pointed foreign bodies – Metallic pins, pointed dentures, fish or meat bones • Instrumental trauma – During esophagoscopy, foreign body removal or dilatation of strictures with bougies • Spontaneous – Usually follows vomiting	• Just above upper sphincter (during instrumental trauma)—cervical • Lower third esophagus (spontaneous rupture)—thoracic

Clinical Features

Symptoms	*Signs*
• History of esophagoscopy • Pain in neck, chest, epigastrium referred to interscapular region • Fever	• Local tenderness • Surgical emphysema in neck • Crunching sound over heart—Hamman's sign (due to air in mediastinum and pneumothorax) • Signs of shock like fall in BP and raised pulse rate

Investigations

- X-ray chest and neck
  - Widening of mediastinum and retrovisceral space
  - Surgical emphysema
  - Pneumothorax
  - Pleural effusion
  - Gas under diaphragm.

Treatment

	Conservative	*Operative*
Indications	• Early perforations	• Progressive surgical emphysema • Evidence of pleural effusion • Worsening of patients general condition • Formation of mediastinal abscess
Technique	• Stop all oral feeds immediately • Parenteral nutrition • Systemic antibiotics intravenously in massive doses • Steroids in large doses	• Repair of perforation • Drainage of retrovisceral space and/or upper mediastinum if suppuration develops

CHAPTER 52: HEAD AND NECK SPACE INFECTIONS

Long Essays

1. Enumerate the ENT conditions presenting with trismus. Discuss the etiopathology, clinical features and management of peritonsillar abscess (Quinsy).	319, 180	D03, J17
2. Discuss the etiopathology, clinical features and management of deep neck space infections.	105	D09(RS2)
3. Describe the anatomy of retropharyngeal space. Discuss the etiopathogenesis, clinical features and management of (acute) retropharyngeal abscess.	105	D14(RS3), J07, J09(OS)
4. Name the two types of retropharyngeal abscess. Describe the etiology, pathogenesis, clinical features and treatment of any one of them.	106	D00

Short Essays

1. Ludwig's angina.	198	D11(RS2), D15(RS3), D17(RS3), J01, J13, D00(OS), D11(OS)
2. Peritonsillar abscess (quinsy)—define, etiopathogenesis, clinical features and management.	180	J11(RS2), J14(RS3), D15(RS3), D16(RS3), J01, D01, J02, J08, D08, D10, J12, J00(OS), J01(OS), J03(OS), D05(OS), J07(OS), J10(OS), D11(OS), J13(OS), J14(OS)
3. Retropharyngeal abscess—etiology and management.	106	J08(RS2), J14(RS3), J09
4. Acute retropharyngeal abscess—etiology, clinical features and management.	107	D13(RS3), D08, D11, J12, D16(OS)
5. Chronic retropharyngeal abscess.	107	J16(RS3), D02
6. Tuberculous cervical lymphadenitis.	363	J07, J14
7. Parapharyngeal space (anatomy and its surgical approaches).	106	J17(RS3), J02(OS), D08(OS)
8. Parapharyngeal space abscess.	108	D14, D15

Short Answers

1. Ludwig's angina.	198	D10(RS2), J16(RS3), J17(RS3), D05, J09, D99(OS)
2. Peritonsillar abscess (quinsy).	180	D07(RS2), J16, D16, D01(OS), J02(OS), D02(OS)
3. Space of Gillette.	106	D01, J02, J05
4. Acute retropharyngeal abscess.	107	D16
5. Parapharyngeal space.	106	D12(RS3), J03
6. Parapharyngeal abscess.	108	J10

CHAPTER 53: TUMORS OF OROPHARYNX

Short Essays

1. Etiology of oropharyngeal cancer.	35	J08(RS2)
2. Eagle's syndrome.	147	J10(RS2), D08, J05(OS)

Short Answers

1. Mention the risk factors of cancer oropharynx.	35	J16(OS)
2. Elongated styloid process (Eagle's syndrome).	147	D14(RS3), J02, D11, J10(OS)

CHAPTER 54: TUMORS OF THE HYPOPHARYNX AND PHARYNGEAL POUCH

Short Essay

1. Post-cricoid malignancy.	33	J08(RS2)

CHAPTER 55: SNORING AND SLEEP APNEA

Short Essay

1. Obstructive sleep apnea syndrome.	144	J10(RS2), D10(RS2), D12(RS3), D14(RS3), J17

Short Answer

1. Sleep apnea.	144	D09(RS2), J13

SECTION IV: DISEASES OF PHARYNX

CHAPTER 47: ANATOMY AND PHYSIOLOGY OF PHARYNX

Short Essays

1. Describe in detail the surgical approaches to nasopharynx.	340	J17(RS3)
2. Killian's dehiscence.	279	D11
3. What is Killian's dehiscence? Discuss management of pharyngeal pouch.	279	J14(RS3)
4. Describe the Waldeyer's ring? Explain its importance.	299	J15(RS3), J03, J02(OS), J09(OS)
5. Pyriform fossa.	89	J09(RS2)

Short Answers

1. Killian's dehiscence.	279	D11(RS2), J12(OS)
2. Waldeyer's ring.	299	D09(RS2), J11(RS2), D12(RS3), D13(RS3), D16(RS3), D08, J10, J07(OS)
3. Fossa of Rosenmuller.	296	D14(RS3)
4. Pyriform sinus (fossa).	89	J15(RS3), D15(RS3)

CHAPTER 48: ADENOIDS AND OTHER INFLAMMATIONS OF NASOPHARYNX

Short Essays

1. Etiology, clinical features and management of adenoiditis.	322	J16(RS3), J04
2. Adenoid facies.	323	D11(RS2), D02, D99(OS), J00(OS), D12(OS)

Short Answer

1. Adenoid facies.	323	J12(RS2), J13(RS3), J14(RS3), D10, J14, J17, D02(OS)

CHAPTER 49: TUMORS OF NASOPHARYNX

Long Essays

1. Discuss the etiopathology, clinical features, diagnosis and management of juvenile nasopharyngeal angiofibroma (JNA).	102	D09(RS2), J11(RS2), D16(RS3), J01, D01, D08, D14, D12(OS)
2. Discuss etiopathology, clinical features and management of carcinoma, nasopharynx.	27	J08(RS2)

Short Essays

1. Juvenile nasopharyngeal angiofibroma (JNA)—clinical features, diagnosis, management.	102	D10(RS2), D12(RS3), J15(RS3), J04, D05, J09, D12, J02(OS)
2. Carcinoma nasopharynx—management.	27	J06, D06, D01(OS), J03(OS)

Short Answers

1. Frog face deformity.	103	J12(OS)
2. Trotter's triad in nasopharyngeal carcinoma.	29	J06(OS)

CHAPTER 50: ACUTE AND CHRONIC PHARYNGITIS

Short Essays

1. Describe tonsillar keratosis.	315	D00
2. Write short note on keratosis pharyngitis.	315	J06

Short Answers

1. Hyperkeratosis of tonsil.	315	D10
2. Keratosis pharyngis.	315	D15(RS3)

CHAPTER 51: ACUTE AND CHRONIC TONSILLITIS

Long Essays

1. Discuss the etiopathology, clinical diagnosis and management of acute tonsillitis.	374	J13(OS)
2. Enumerate the conditions causing patch on the tonsils and their management.	207	D02, D04
3. Discuss the types, clinicopathological features and management of chronic tonsillitis.	305	J10, D07(OS)

Short Essays

1. Anatomy of palatine tonsil.	127	D15
2. Acute tonsillitis—clinical features and management.	374	D12
3. Membranous tonsillitis.	143	J10(RS2)
4. Differential diagnosis (causes) of a white patch (membrane) on the tonsil.	207	D11(RS2), J16(RS3), J17(RS3), J04, J06, J07, D10(OS)
5. How would you diagnose and treat tonsillar diphtheria?	376	D10
6. Chronic tonsillitis—clinical features (cardinal signs) and management.	305	D06, D13

Short Answers

1. Anatomy of palatine tonsil.	127	D06
2. Lateral relations of tonsils.	128	D11
3. Blood supply of palatine tonsil.	129	D09(RS2), D11(RS2), D07, J12, D12
4. Mention types of acute tonsillitis.	374	D12(OS)
5. Membranous conditions of tonsil.	208	D07(RS2)
6. Cardinal signs of chronic tonsillitis.	305	J15(RS3), J16(RS3), D05
7. Enumerate complications of chronic tonsillitis.	306	D14
8. Tonsillolith.	352	D17(RS3), J13
9. Lingual tonsillitis.	368	D02, J05

SECTION V: DISEASES OF LARYNX AND TRACHEA

CHAPTER 56: ANATOMY AND PHYSIOLOGY OF LARYNX

Long Essay

1. Discuss the physiology of phonation.	30	J08(RS2)

Short Essays

1. Intrinsic muscles of larynx.	31	J08(RS2)
2. Differences between adult and infant's larynx.	89	J09(RS2), D11(RS2), D15
3. Functions of larynx.	242	D12(RS3)
4. Describe the mechanism of phonation.	30	D10(OS)

Short Answers

1. Laryngeal cartilages .	96	J09(RS2)
2. Unpaired cartilages of larynx.	96	D11, J06(OS)
3. Tensors of the vocal cords.	32	D06(OS)
4. Differences between adult and infant larynx.	89	D10(RS2)
5. Functions of larynx.	242	I10(RS2), D14

CHAPTER 57: LARYNGOTRACHEAL TRAUMA

Long Essay

1. Discuss the etiopathology, clinical features and management of laryngotracheal trauma.	307	D15(RS3)

CHAPTER 58: ACUTE AND CHRONIC INFLAMMATIONS OF LARYNX

Short Essays

1. Acute epiglotitis (clinical features and management).	35	J08(RS2), D17(RS3), D12
2. Laryngeal diphtheria.	376	D14
3. Tuberculosis of larynx.	377	J15

Short Answers

1. Epiglottitis in children.	35	D00, D04
2. Acute epiglottitis.	35	D01(OS)
3. Management of acute epiglotitis.	36	D14(RS3)
4. Reinke's edema.	150	J10(RS2), J11(RS2), D16(RS3), D14
5. Features of tubercular laryngitis.	377	J09

CHAPTER 59: CONGENITAL LESIONS OF LARYNX AND STRIDOR

Long Essays

1. Define stridor. Enumerate the causes of stridor. How do you manage a patient of stridor?	320	J16(RS3), J03, J11
2. Classify the causes of stridor in a child. Discuss the clinical features and management of juvenile laryngeal papillomatosis.	320, 15	D05

Short Essays

1. Laryngomalacia (congenital laryngeal stridor).	122	D09(RS2), J14, D99(OS)
2. Subglottic stenosis.	369	J17
3. Stridor—define, causes (in children).	320	J14(RS3), D00, D04, J16, D02(OS)

Short Answers

1. Laryngomalacia.	122	D15(RS3), J07, J12, D02(OS), J11(OS)
2. Subglottic stenosis.	369	J01
3. Laryngeal web.	330	J16(RS3), D02, J05, J16
4. Stridor.	320	J12(RS2), J13(RS3), D13(RS3), J13(OS)
5. Etiology of stridor in children.	320	J15(RS3)
6. Enumerate causes of congenital laryngeal stridor.	122	J10

CHAPTER 60: LARYNGEAL PARALYSIS

Short Essays

1. Nerve supply of larynx.	311	D15(RS3)
2. Difference between the right and left recurrent laryngeal nerve anatomy.	130	J05
3. Enumerate the causes of vocal cord paralysis. How do you investigate and manage a case of unilateral vocal cord paralysis.	353	J02, D04
4. Discuss the causes of unilateral vocal cord palsy.	353	D07(OS)
5. Causes of left recurrent laryngeal nerve paralysis.	353	D06
6. What is Dysphagia? Mention the causes of left recurrent laryngeal palsy.	173, 353	J14(OS)

Short Answers

1. Causes of left vocal cord paralysis.	353	J17
2. Recurrent laryngeal nerve.	129	D09(RS2)
3. Bilateral adductor paralysis.	151	J10(RS2)

CHAPTER 61: BENIGN TUMORS OF LARYNX

Long Essay

1. Discuss the etiopathology, clinical features, management and complications of juvenile laryngeal papilloma.	15	J15(RS3)

Short Essays

1. Singer's nodule (vocal nodule).	325	J16(RS3), J04, J07, D08, D10, D13, J03(OS), J05(OS), D06(OS), D09(OS)
2. Vocal polyp (etiopathology and management).	43	J06, D03(OS)
3. Give an account of laryngocele.	350	D01, J05, J07, J12
4. Papillomas of larynx.	14	D07(RS2)
5. Juvenile laryngeal papillomatosis.	15	D17(RS3), D13
6. Discuss in brief multiple papillomas of larynx.	14	J08, J12(OS)
7. Recurrent laryngeal papilloma.	15	D03(OS)

Short Answers

1. Premalignant lesions of larynx.	286	J14(RS3)
2. Vocal nodule (Singer's nodule/laryngeal nodules)—management.	325	J14(RS3), D14(RS3), D17(RS3), J01, D01, D03, J08, D12, J13, D15, J17, J00(OS), J02(OS), J11(OS)
3. Vocal cord polyps.	43	J08(RS2), J11(RS2), D12(RS3), D16(RS3), J10
4. Laryngocele.	350	D17(RS3)
5. Laryngeal papilloma.	14	J15(RS3)

CHAPTER 62: CANCER LARYNX

Long Essays

1. Describe the etiology, symptoms, signs, investigations and treatment of carcinoma larynx.	158	D10(RS2)
2. How do you manage a stage III carcinoma larynx?	163	D07(RS2)

Short Essays

1. Pharyngocutaneous fistula.	38	J08(RS2)
2. Glottic cancers have high cure rate. Give reasons.	366	D00, J03, D04
3. TNM classification of carcinoma of glottis.	162	J15
4. Carcinoma of the vocal cord.	159	D99(OS)
5. Mention signs and symptoms of carcinoma glottis. How do you do staging of the same?	160	J13(OS)
6. Investigations and treatment of glottic cancer.	161	J04
7. Treatment of carcinoma larynx (T1 lesion).	163	J00(OS)
8. Speech rehabilitation following laryngectomy.	378	D05

Short Answers

1. TNM classification of carcinoma larynx.	162	D07
2. T1 glottic malignancy.	162	D03
3. Esophageal voice.	378	D00, D02, D04, J05

CHAPTER 63: VOICE AND SPEECH DISORDERS

Short Essays

1. Discuss the management of an adult patient presenting with hoarseness of voice.	8	J17(RS3)
2. 'Hoarse voice'—causes (in 50 years old male).	7	D07(RS2), D13
3. Functional aphonia.	151	D05, D11
4. Puberphonia.	134	D07(OS)
5. Rhinolalia.	72	J10

Short Answers

1. Enumerate causes of hoarseness in 50 years old female.	7	J10
2. Sudden aphonia.	151	D05(OS)
3. Puberphonia.	134	D09(RS2), J11, J15, D99(OS), J02(OS), D03(OS)
4. Rhinolalia.	72	D08(RS2)
5. Rhinolalia aperta (causes).	72	D01, J02, J13(OS)
6. Rhinolalia clausa.	72	J03, J16, J05(OS)

CHAPTER 64: TRACHEOSTOMY AND OTHER PROCEDURES FOR AIRWAY MANAGEMENT

Long Essay

1. Tracheostomy—define, indications, surgical procedure, postoperative care and complications.	9	J05(OS), D06(OS), J07(OS), J16(OS)

Short Essays

1. Advantages of tracheostomy over endotracheal intubation.	12	D06
2. Tracheostomy—types, indications (nonobstructive), procedure and complications.	9	D07(RS2), D08(RS2), J11(RS2), D12(RS3), J15(RS3), D16(RS3), J17(RS3), J04, D04, J08, J10, D14, J17, D00(OS), D07(OS), D12(OS)
3. Postoperative management after tracheostomy.	11	J03(OS)
4. What is emergency tracheostomy? Name the indications for it.	9	D02

Short Answers

1. Indications for tracheostomy.	9	D10(RS2), J12
2. Nonobstructive indication for tracheostomy.	9	D15
3. Decannulation of tracheostomy.	12	D11
4. Causes of decanulation problem.	12	D03
5. Complications of tracheostomy.	12	D05, J08, J16
6. Cricothyrotomy.	369	D01(OS)

CHAPTER 65: FOREIGN BODIES IN AIR PASSAGE

Short Essay

1. Foreign body in bronchus.	184	J11(RS2), D16(RS3), J13, D16

SECTION III: DISEASES OF ORAL CAVITY AND SALIVARY GLANDS

CHAPTER 42: ANATOMY OF ORAL CAVITY

None

CHAPTER 43: COMMON DISORDERS OF ORAL CAVITY

Short Essays

1. Vincent's angina.	362	J03, D06(OS)
2. Oral submucous fibrosis.	146	J10(RS2), J14(RS3), D00, J02, D04

Short Answer

1. Vincent's angina.	362	D00(OS), D03(OS)

CHAPTER 44: TUMORS OF ORAL CAVITY

Short Essays

1. Premalignant conditions of the oral cavity.	18	D14, J06(OS)
2. Leukoplakia.	18	D12

Short Answers

1. Ranula.	187	J11(RS2), D11(RS2), D16(RS3), J14
2. Premalignant conditions of oral cavity.	18	D07(RS2), J10
3. Leukoplakia (of oral cavity/tongue).	18	D17(RS3), D00, J02, D04, J07

CHAPTER 45: NON-NEOPLASTIC DISORDERS OF SALIVARY GLANDS

Short Essay

1. Management of sialolithiasis.	347	D05

Short Answers

1. Submandibular salivary calculus.	347	D01
2. Treatment of salivary calculi.	347	J17(RS3)

CHAPTER 46: NEOPLASMS OF SALIVARY GLANDS

Short Essay

1. Parotid neoplasms.	293	D14(RS3)

Short Answer

1. Pleomorphic adenoma (clinical features).	274	D13(RS3), D06

SECTION VI: THYROID GLAND AND ITS DISORDERS

CHAPTER 66: THYROID GLAND AND ITS DISORDERS

Short Essay

1. Lingual thyroid.	34	J08(RS2)

Short Answer

1. Lingual thyroid.	34	J12(RS2), J13(RS3)

SECTION VII: DISEASES OF ESOPHAGUS

CHAPTER 67: ANATOMY AND PHYSIOLOGY OF ESOPHAGUS

Long Essay

1. Discuss the physiological basis and mechanism (phases) of deglutition.	44	D08(RS2), J14

Short Essay

1. Describe the mechanism of deglutination.	44	J01(OS)

Short Answer

1. Constrictions of esophagus.	314	D15(RS3)

CHAPTER 68: DISORDERS OF ESOPHAGUS

Short Essays

1. Esophageal perforation.	21	J16(OS)
2. Plummer-Vinson (Paterson Brown Kelly) syndrome.	292	D14(RS3), D05, J07, D13, J07(OS), D09(OS), J10(OS)
3. Globus hystericus.	233	D06
4. Achalasia cardia.	379	J07, D00(OS), D07(OS), J12(OS)

Short Answers

1. Esophageal perforations.	21	D07(RS2)
2. Plummer-Vinson (Patterson Kelly) syndrome.	292	J15(RS3), J08, J03(OS), J16(OS)
3. Globus pharynges (globus hystericus).	233	J12(RS2), J13(RS3), J11
4. Achalasia cardia.	379	D03(OS)

CHAPTER 69: DYSPHAGIA

Long Essay

1. How will you manage a case of 50 years old woman presenting with dysphagia.	173	D15

Short Essays

1. Dysphagia—causes/management.	173	D10(RS2), D17(RS3), J02, J15, J02(OS), D02(OS)
2. Dysphagia lusoria.	174	D11

Short Answer

1. Dysphagia lusoria.	174	J11(OS)

CHAPTER 70: FOREIGN BODIES IN FOOD PASSAGE

Short Essay

1. Clinical features and management of foreign bodies in esophagus.	380	J09

Short Answers

1. Foreign body in cricopharynx.	380	D10